

Peripheral ossifying fibroma – A case report

Rubeena M. Raffi^{1*}, Shubha C², Sujatha G.P³, Ashok L.⁴

¹Postgraduate, ²Reader, ³Professor, ⁴Professor and HOD, ¹⁻⁴Dept. of Oral Medicine and Radiology, ¹⁻⁴Bapuji Dental College and Hospital, Davangere, Karnataka, India

***Corresponding Author: Rubeena M. Raffi**

Email: rubeenamraffi973@gmail.com

Abstract

Peripheral ossifying fibroma (POF) is a reactive inflammatory gingival hyperplasia which shows area of calcification or ossification. It is a non-neoplastic entity of gingiva. The etiology and pathogenesis of POF are yet not clear, but hypothesized as a proliferative reaction originating from the periodontal ligament, as a result of irritating agents such as dental calculus, plaque, orthodontic appliances, and overhanging restorations. The clinical presentation as mass and radiographic presentation of soft tissue calcification may lead to misclassification; however the histologic appearance is diagnostic. We are presenting a case of peripheral ossifying fibroma in a 48 year old female who reported to us with painless growth on upper right gum region since two months.

Keywords: Ossifying fibroma, Reactive lesion, Gingival growth.

Introduction

The gingiva is subjected to constant local irritation or trauma from calculus deposits, food lodgement, restorations that have faulty margins, low-grade trauma, trauma while brushing teeth and iatrogenic factors.^{1,4} It reacts to these irritants with localized hyperplasia that can be composed of mature collagen, cellular fibroblastic tissue, mineralized tissue, endothelial cells, and multinucleated giant cells. These localized overgrowths are not considered as being neoplasms but rather hyperplastic inflammatory reactions. Localized reactive lesions seen on the gingiva includes focal fibrous hyperplasia, pyogenic granuloma, peripheral giant cell granuloma, and peripheral ossifying fibroma (POF).² Peripheral ossifying fibroma presents as gingival swelling that is considered to be reactive in nature rather than neoplastic nature.³ This may originate from the periosteum and periodontal ligament as a result of constant irritation by deposits of plaque and calculus, orthodontic appliances, and faulty restorations.⁴ It is typically seen as an epulis on interdental papilla and comprises about 9% of all gingival growths.² Females are more commonly affected, and most prevalent location is maxillary arch and most of them occur in incisor and cuspid region. The lesion reaches a size of 2 cm and typically self-limiting, however it has been recognized that some POF may grow quite large and may displace teeth. POF is a non neoplastic entity, which is a reactive lesion of gingiva and not the soft tissue counterpart of central ossifying fibroma. POF presents clinically as a benign lesion. Incidences of recurrence have been reported to be 7–45%. The possible reasons for increased recurrence rate is incomplete surgical excision of lesion, incomplete removal of plaque and calculus deposits, and difficulty in access during surgical manipulation due to intricate location of POF being present usually at interdental areas.⁶

Case Report

A 48 year old female patient reported to department of oral medicine and radiology with a complaint of painless growth in right upper front gum region since 2 months. She

presented with a history of occasional bleeding from gingival growth while brushing teeth. On examination of soft tissue a solitary mass was present on the marginal and attached gingiva of 11, round in shape, 1x1cm in size, sessile, mucosa over it appeared erythematous on inferior aspect and pink on superior aspect. On palpation the lesion was firm in consistency, non-tender. On hard tissue examination 11 is slightly palatally displaced and about 1mm below the plane of occlusion. Provisional diagnosis of epulis irt 11 region was given, differential diagnosis included focal fibrous hyperplasia, pyogenic granuloma, peripheral ossifying fibroma and peripheral giant cell tumor. On intraoral periapical radiograph irt 11 revealed thickening of lamina dura and widening of PDL space present in cervical one third of root on distal aspect of 11 and mesial aspect of 12.

Routine hematologic investigations and serology tests were done before excisional biopsy which were all within normal limits. Oral prophylaxis was done and after three weeks surgical excision of lesion was done. Histopathology report revealed presence of parakeratinised stratified squamous epithelium and connective tissue appears hypercellular with osteoid area and containing chronic inflammatory cells. Based on histopathologic examination and clinical presentation final diagnosis of peripheral ossifying fibroma irt 11 region was given.

Discussion

Most of the localised growth in oral cavity is seen on gingiva which may range from inflammatory or reactive to neoplastic in nature. Peripheral ossifying fibroma is one such reactive, non-neoplastic entity. It is a focal reactive hyperplasia of connective tissue that occurs exclusively on gingiva. It accounts for 9.6% of gingival lesions.^{7,9,20} POF is well demarcated mass of tissue, located on the gingiva, having a sessile or pedunculated base, and being the same color as normal mucosa or slightly reddened⁸. Synonyms of POF are peripheral cementifying fibroma, ossifying fibroepithelial polyp, peripheral odontogenic fibroma with

cementogenesis, peripheral fibroma with osteogenesis, peripheral fibroma with cementogenesis, peripheral fibroma with calcification, calcifying or ossifying fibroid epulis, calcifying fibroblastic granuloma, mineralizing ossifying pyogenic granuloma.

Shepherd in the year 1855 reported first case of peripheral ossifying fibroma was reported as Alveolar exostosis. The lesion was first described as a relatively uncommon, solitary, nonneoplastic gingival growth by Eversol and Robin. The term “Peripheral ossifying fibroma” was coined by Gardner in 1982 for a lesion that is reactive in nature, and it is not the extraosseous counterpart of a central ossifying fibroma of the maxilla and mandible.^{4,11,12} In the literature, the central and the peripheral types of ossifying fibroma have been cited. Central ossifying fibroma is a fibro-osseous lesion of the maxilla and mandible. Peripheral ossifying fibroma is a reactive lesion accounting for about 2% of all oral lesions that are biopsied. Ossifying fibroma histologically contains bone, cementum and spheroidal calcification, which has given rise to various terms for these benign fibro-osseous neoplasm. Where in ‘ossifying’ term is used when bone predominates, ‘cementifying’ term is used trabeculae or spherical calcification are seen. ‘Cemento-ossifying fibroma’ term is used when histologically both bone and cementum are seen. Cementifying fibroma are clinically and radiographically impossible to separate from ossifying fibroma, they can be only diagnosed histopathologically.¹³

Etiopathogenesis remains controversial and there are two schools of thought proposed to understand the histogenesis of POF.

1. Pyogenic granuloma may undergo fibrous maturation and calcification, and develop as peripheral ossifying granuloma.
2. The cells of periodontal ligament or periosteum may undergo inflammatory hyperplasia. Followed by metaplastic changes of connective tissue leading to dystrophic calcification and bone formation.¹⁰

The etiology and pathogenesis of POF is not clear. Since POF predominantly appears in gingival tissue close to periodontal ligament it is proposed that POF is derived from the cells of periodontal ligament. Within the mineralized matrix of lesions oxytalan fibres are found which are the micro fibrils seen in periodontal ligaments. The distribution of lesions are seen more in older age group with inverse proportional relation to number of permanent teeth lost. The other reactive gingival lesions arising from periodontal ligament has indistinguishable fibrocellular response as POF.

Furthermore, high female propensity, less frequent occurrence in the first decade, and decreased occurrence after 30 years of age suggests that hormonal influence may be a lesional growth factor.⁷ However, an immunohistochemical study on 4 female cases of POF did not show estrogen or progesterone receptor positivity.¹⁹ Other factors that have been implicated in the etiopathogenesis of POF are trauma

and local irritants such as deposits of plaque and calculus, ill-fitting dental appliances and microorganisms.²¹

Peripheral ossifying fibroma shows female predilection, average age of occurrence is 34.76 years. These lesions have an average duration of 18.6 months. These lesions are seen most commonly in maxillary arch than in mandible and incisors-cuspids are involved often.¹⁵ POF is a solitary, slow growing well circumscribed mass that is either pedunculated or it can be sessile.^{14,21} The mucosa over the lesion may vary from pink to reddish pink in colour. The surface can be smooth or irregular and lobulated, it may be ulcerated or non-ulcerated. The size may vary from 0.2 to 3cm. Most common site is interdental papilla.⁴ Bone destruction in interdental region with migration of teeth is reported.¹⁴ On palpation the growth is non-tender and firm in consistency. In large number of cases on radiographic examination no obvious bone involvement is evident. However, superficial erosion of bone is noted occasionally. Irregular radiopacity can be seen interspersed in the soft tissue shadow.

Differential diagnosis of peripheral ossifying fibroma can be focal fibrous hyperplasia, pyogenic granuloma and peripheral giant cell granuloma. Focal fibrous hyperplasia is more common among women, and the peak age is in the third to sixth decade, with the anterior maxilla being the most prevalent site. Clinically it appears as pale pink to white in colour, less than 2cm in diameter, firm in consistency, sessile growth. Pyogenic granuloma is more common among women, and the anterior maxilla is the most prevalent site. Clinically presents as reddish to pink in colour, less than 2.5 cm in diameter, soft in consistency, pedunculated growth. Peripheral giant cell granuloma peak age ranges between the fourth and sixth decades, and the posterior mandible is the most prevalent site. Clinically presents as reddish purple in colour, 1 to 1.5cm in size, firm and pedunculated growth.^{3,16,23} Radiographically POF shows thickening of lamina dura and widening of periodontal ligament space of involved teeth, there can be interspersed foci of calcification in the soft tissue shadow.¹⁷ Occasionally foci of radiopaque material, particularly in larger lesions or mild cupping defect of adjacent alveolar bone may be seen.²⁰

Histologically, the POF consists of intact or ulcerated stratified squamous epithelium, cell rich connective tissue stroma containing proliferating fibroblasts intermingled with fibrillar tissue, mineralized components, chronic inflammatory cells, sparse to profuse endothelial proliferation. Mineralized components often present vary both in constitution and amount. Mineralized tissue observed in POF are – woven bone trabeculae, lamellar bone trabeculae, circumscribed amorphous appears as droplets of calcified material closely resembling acellular cementum or cementum-like droplets, and granular foci of mineralization (dystrophic calcifications) appears as as conglomerate of very small basophilic granules, tiny globules, and small, solid, irregular masses. The ulcerative lesion showed presence of dystrophic calcification.^{18,5} Treatment of POF includes thorough oral prophylaxis, root planning of adjacent teeth and other source of irritants should be

removed. Surgical intervention of POF should ensure deep incision of lesion including periosteum. Due to increased recurrence rates regular follow up is essential. Incomplete excision of lesion and/ or due to perseverance of local factors is the possible reason for recurrence. Recurrence rates have been reported from 7% to 45%.^{18,4}

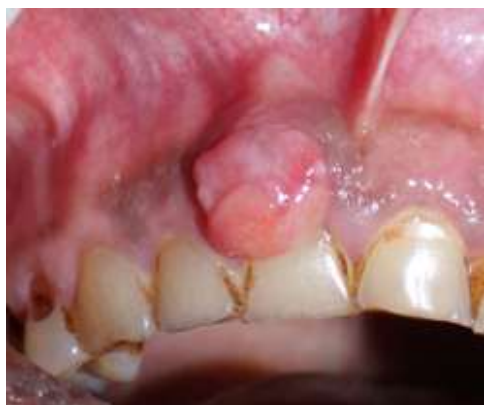

Fig. 1: Solitary gingival growth irt 11.

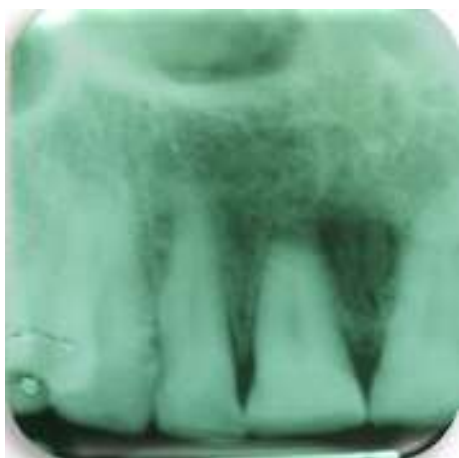


Fig. 2: IOPA irt 11 showing thickening of lamina dura and widening of PDL space on distal aspect of cervical 1/3 of root.

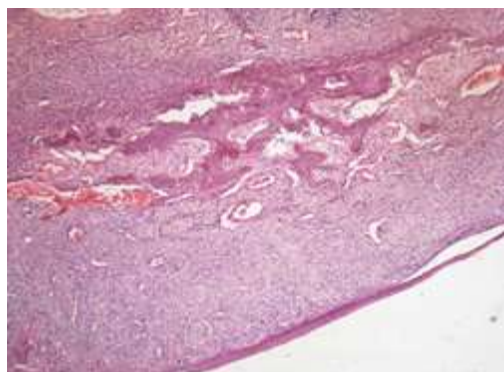


Fig. 3: Histopathologic section showing parakeratinised squamous epithelium and connective tissue appears hypercellular with osteoid area and containing chronic inflammatory cells

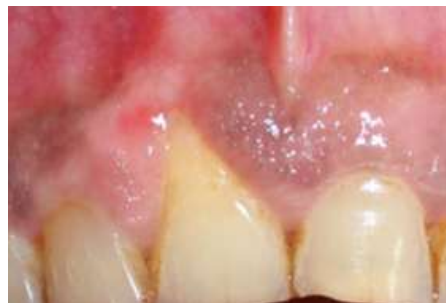

Fig. 4: Post-operative photograph 15 days after surgical removal.

Conclusion

Gingiva is the commonest site subjected to continuous local irritation or trauma by deposits of plaque and calculus, food lodgement, faulty restorations, low grade trauma. It reacts to these irritants with localized hyperplasia that can be composed of mature collagen, cellular fibroblastic tissue, mineralized tissue, endothelial cells, and multinucleated giant cells. Epulis being one of the commonest solitary swelling in the oral cavity is many times clinically diagnosed as pyogenic granuloma. Substantial overlap exists between various focal reactive overgrowths of gingiva. Therefore a careful history and clinical and radiographic examination is absolutely necessary to arrive at the diagnosis

Conflict of Interest: None.

References

1. Buchner A, Calderon S, Ramon Y. Localized hyperplastic lesions of the gingiva: a clinicopathological study of 302 lesions. *J Periodontol* 1977;48:101-4.
2. Bhaskar SN and Jacoway JR, "Peripheral fibroma and peripheral fibroma with calcification: report of 376 cases," *J Am Dent Assoc* 1966;73(6):1312-20.
3. Buchner A, Shnaiderman-Shapiro A, Vered M. Relative frequency of localized reactive hyperplastic lesions of the gingiva: a retrospective study of 1675 cases from Israel. *J Oral Pathol Med* 2010;39(8):631-8.
4. Eversole LR, Robin S. Reactive lesions of the gingiva. *J Oral Pathol* 1972;1:30-8.
5. Neville BW, Damm DD, Allen CM, Bouquot JE. Oral and Maxillofacial Pathology. 3rd ed. St. Louis: Elsevier; 2009:451-452.
6. Shetty DC, Urs AB, Ahuja P, Sahu A, Manchanda A, and Sirohi Y et al, "Mineralized components and their interpretation in the histogenesis of peripheral ossifying fibroma," *Indian J Dent Res* 2011;22(1):56-61.
7. Shetty P, Adyanthaya S. Peripheral ossifying fibroma-a clinical and histological evaluation of 51 cases. *People's J Sci Res* 2012;5(1):9-14.
8. Rajendran R. Shafer's Textbook of Oral Pathology. 7th ed. Philadelphia: Elsevier; 2012:133-134.
9. Mishra MB, Bhishen KA, Mishra S. Peripheral ossifying fibroma. *J Oral Maxillofac Pathol* 2011;15:65-8.
10. Prasad S, Reddy SB, Patil SR, Kalburgi NB, Puranik RS. Peripheral ossifying fibroma and pyogenic granuloma. Are they interrelated? *N Y State Dent J* 2008;74:50-2.
11. Reddy GV, Reddy J, Ramlal G, Ambati M. Peripheral ossifying fibroma: Report of two unusual cases. *Indian J Stomatol* 2011;2:130-3.

12. Gardner DG. The peripheral odontogenic fibroma: an attempt at classification. *Oral Surg Oral Med Oral Pathol* 1982;54:40.
13. Yadav R, Gulati A. Peripheral ossifying fibroma: a case report. *J oral Sci* 2009;51(1):151-4.
14. Poon CK, Kwan PC, and Chao SY, "Giant peripheral ossifying fibroma of the maxilla: report of a case," *J Oral Maxillofac Sur* 1995;53(6):695–8.
15. Bhaskar SN, Jacoway JR. Peripheral fibroma and peripheral fibroma with calcification: report of 376 cases. *J Am Dent Assoc* 1966;73(6):1312-20.
16. Shamim T, Varghese VI, Shameena PM, Sudha S. A retrospective analysis of gingival biopsied lesions in South Indian population: 2001-2006. *Med Oral Patol Oral Cir Bucal* 2008;13(7):E414-8.
17. Bhasin M, Bhasin V, Bhasin A. Peripheral ossifying fibroma. Case reports in dentistry. 2013;2013.
18. Buchner A, Hansen LS. The histomorphologic spectrum of peripheral ossifying fibroma. *Oral Surg Oral Med Oral Pathol Oral Radiol* 1987;63(4):452-61.
19. Gracia de Marcos JA, Gracia de Marcos MJ, Rodriguez SA, Rodrigo JC, Poblet E: Peripheral ossifying fibroma: a clinical and immunohistochemical study of 4 cases. *J Oral Sci* 2010;52(1):95-9.
20. Shah JS, Sharma S. Peripheral ossifying fibroma: An unusual presentation. *Int J Oral Health Sci* 2018;8(1):47.
21. Kaur M, Kumar K. Peripheral ossifying fibroma-an uncommon occurrence in mandible. *Int J Appl Dent Sci* 2018;4(3):207-8.
22. De Souza Mp, De Andrade Zg, De Freitas Ct, Santos So, Batista Fa, Camara J. Peripheral ossifying fibroma in maxilla: case report. *Oral Sur; Oral Med Oral pathol Oral Radiol* 2017;124(2):e102-3.
23. Hasanuddin S, Babu PR. Peripheral Ossifying Fibroma: A Very Rare Clinical Presentation. *Indian J Dent Advancements* 2017;9(3):197-200.
24. Monteiro Mj, De Brito Tc, Conde Nc, Domingues Je. Peripheral ossifying fibroma: case report. *Oral Surg Oral Med Oral Pathol Oral Radiol* 2017;124(2):e114.
25. Reddy V, Arunkumar KV, Wadhwan V, Venkatesh A. Giant Peripheral Ossifying Fibroma of the Posterior Mandible-A Rare Case Report. *Iranian J Pathol* 2017;12(4):397.

How to cite this article: Raffi RM, Shubha C, Sujatha GP, Ashok L, Peripheral ossifying fibroma – A case report. *Int Dent J Student's Res* 2019;7(2):43-6.