

## “Keles transpalatal arch for molar derotation”- Clinical discussion

Devaki Vijayalakshmi<sup>1</sup>, Saloni Garg<sup>2\*</sup>, Ratna Parameswaran<sup>3</sup>, Srinivasan Boovaraghavan<sup>4</sup>

<sup>1,3,4</sup>M.D.S, <sup>2</sup>B.D.S, Dept. of Orthodontics, Meenakshi Ammal Dental College and Hospital, Alapakkam Main Road, Maduravoyal, Chennai, India

**\*Corresponding Author:**

Email: garg.saloni5@gmail.com

### Abstract

**Aim:** The aim of the article is to describe the effect of Keles Trans Palatal Arch (TPA) on unilateral and bilateral molar rotation illustrated with two case reports.

**Method:** Unilateral and bilateral maxillary first permanent molars de-rotation were performed in two cases using Keles appliance system which consists of the precision lingual hinge cap and TPA made of TMA wire. (0.032 × 0.032") (Ormco, Orange, CA). A 20 degree activation is given to the rotating part/terminal end(s) of the TPA every fourth week until rotation is completely corrected. The de-rotation achieved and change in the intermolar width are assessed using digital cast analysis performed by Ilexis FACAD (AB-2014 version 3.8.00) software and by comparing the pre and post maxillary occlusal radiographs with marker wires.

**Result:** Pre and post values showed that the de-rotation is achieved in both cases. Inter-molar width showed no significant changes in both cases, suggestive of minimal/no expansion.

**Conclusion:** The Keles TPA resulted in better transverse molar control during molar de-rotation owing to its superior precision self-locking design. When Keles TPA is used in correction of unilateral molar rotation, it causes successful de-rotation on the affected side and minimum or no changes on the unaffected side.

### Introduction

Molar relationships have been a matter of major concern to orthodontist since the advent of Angle's classification of malocclusion in 1899, with the maxillary first permanent molar referred to as the "key to occlusion". Later in 1970's Andrews highlighted the deficiencies in the molar relationship as described by Angle. One of the features in his six keys to normal occlusion is "no rotations".<sup>(1)</sup> Today, the final goal to be achieved is ahead of the ideas proposed by Andrews, with more emphasis on mutually protected occlusion and incisal guidance. With these aims in mind, the upper first permanent molars are in limelight again.

As proposed by Lamons and Holmes,<sup>(2)</sup> the position of maxillary first permanent molar is of importance to the clinical orthodontist since space gained by molar de-rotation measure to 1-2 mm. This plays a vital role in planning the treatment for borderline patients.

In most situation Class II and a few Class I malocclusions manifest mesio-palatally rotated and constricted upper molars, which often results in mild to moderate malocclusion.

Transpalatal bars introduced by Goshgarian,<sup>(3)</sup> as an anchorage appliance have been consistently used for bilateral and unilateral de-rotation of molars. The rigid wire and the method of activation brought about intermolar expansion. Variations from the conventional design have emerged either by bringing about a change in the appliance design or by altering wire material. A recently introduced design variation is the Keles Transpalatal Arch<sup>(4)</sup> (TPA) inspired from the Burstone lingual arch system. This article describes the effect of

Keles TPA on unilateral and bilateral molar rotation using two case reports.

### Appliance Design and Construction

The Keles appliance system consisted of the precision lingual hinge cap\* and TPA made of TMA wire\*\* (0.032 × 0.032") (Ormco, Orange, CA). The precision lingual hinge cap<sup>(5)</sup> attachments, designed to accommodate 0.032 × 0.032" beta-titanium alloy (TMA), are welded on to the selected preformed bands by placing them at the center of bands coinciding with the palatal groove on the upper first molars. The bands are then transferred to the impression and study cast is obtained.

The Keles TPA is fabricated using 0.032 × 0.032" beta-titanium alloy.<sup>(4)</sup> A 20 degrees activation<sup>(4)</sup> is given to the rotating part/terminal end (s) of the TPA (on the side of the rotated molar) keeping the other end stable in one site, using symgrid as a template, with the help of a bird beak pliers. (Fig. 1)

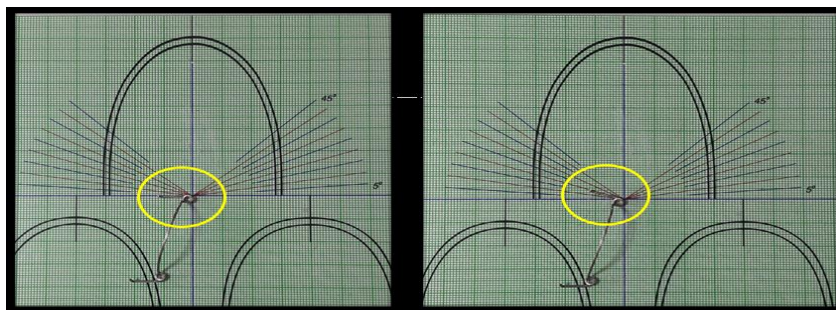
The bands are cemented on to the upper first molars and TPA is inserted into the precision lingual hinge cap<sup>(5)</sup> and locked. Unlike the conventional (removable) Goshgarian<sup>(3)</sup> TPA, Keles TPA self-locking lingual hinge cap does not need a ligature tie to secure the wire component to the lingual attachment.

A maxillary occlusal radiograph is made to evaluate the amount of rotation in the molar with a marker wire (0.019 x 0.025" TMA, 15 mm) in the main slot (Fig. 2 (i)). The TPA is reactivated with 20 degrees every fourth week until rotation is completely corrected. Once the molar (s) is de-rotated, another maxillary occlusal radiograph is made with the marker

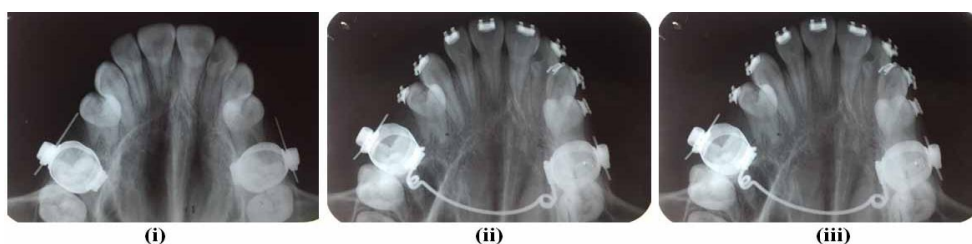
wire in the buccal tube slot to appreciate and evaluate the correction achieved. (Fig. 2 (ii))

The derotation achieved and change in the inter-

molar width are assessed using digital cast analysis performed by Ilexis FACAD (AB-2014 version 3.8.00) software. (Fig. 2 (iii))



**Fig. 1: Keles Transpalatal arch activated by 20 degrees at one arm by keeping the other arm stabilised at one site**



**Fig. 2: (i): Pre-treatment Maxillary Occlusal radiograph with marker wires in the main buccal tube slots. (ii): Post-treatment Maxillary Occlusal radiograph with marker wires in the main buccal tube slots. (iii): Ilexis FACAD (AB-2014 version 3.8.00) software analysis**

### Case 1: Unilateral Molar Rotation

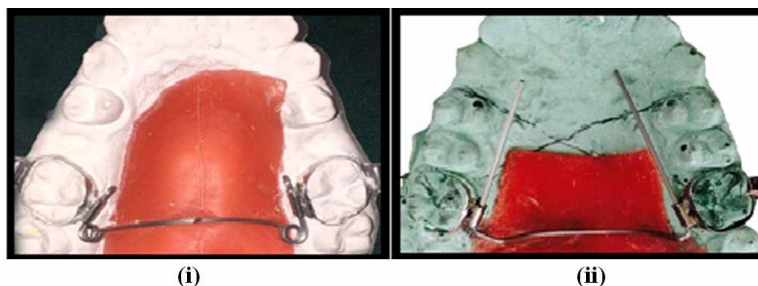
A 12-year-old female patient diagnosed as Angle's Dentoalveolar Class II Division 1 Subdivision malocclusion, on a Class II skeletal base relationship presented at the dental center for orthodontic therapy. The right canine and molar were in 3mm Class II relationship and the left molar and canine in Class I relationship, on a Class II skeletal base, with an average mandibular plane angle. Mesial-in rotation was observed in the upper right first permanent molar. Overbite and overjet were 70% and 3.9 mm. The upper dental midline was coincident with the facial midline, but the lower dental midline was shifted to the right by 2mm. On cast analysis, the arch-length discrepancy was 3.5 mm in the maxilla and 8 mm in the mandible.

Treatment goals were to correct molar rotation and achieve acceptable occlusion with a functional Class I

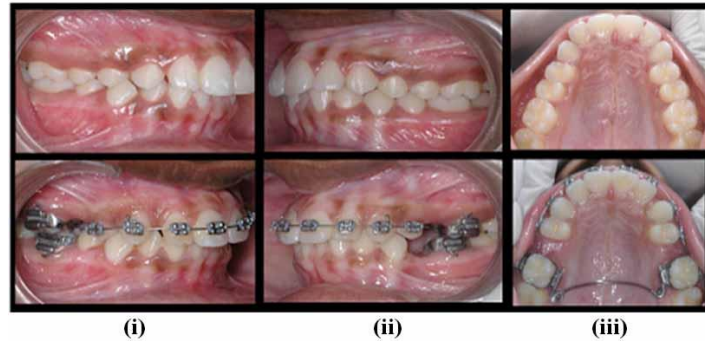
occlusion, and a good facial profile. The treatment mechanics involved fixed orthodontic appliance with 0.022" MBT bracket system.

Unilateral Right maxillary permanent first molar de-rotation performed using "Keles" transpalatal arch ("0.032 × 0.032" beta-titanium alloy TMA, Ormco, Orange, CA) with loops (as in Fig. 3 (i)) combined with all first premolar extractions. Following this, upper strap up was carried out with 0.022" MBT system without involving the upper molars by the arch-wire to assess the unbiased effect of Keles transpalatal arch in de-rotation of the molar.

Keles TPA was given 20 degrees activation at the right terminal end only and similar records were obtained. After the twelfth week following two reactivation intervals, the right molar was completely de-rotated. (Fig. 4)



**Fig. 3: (i): Keles Transpalatal Arch (with loops) without activation fabricated on a working model. (ii): Keles Transpalatal arch (without loops) without activation fabricated on a working model**



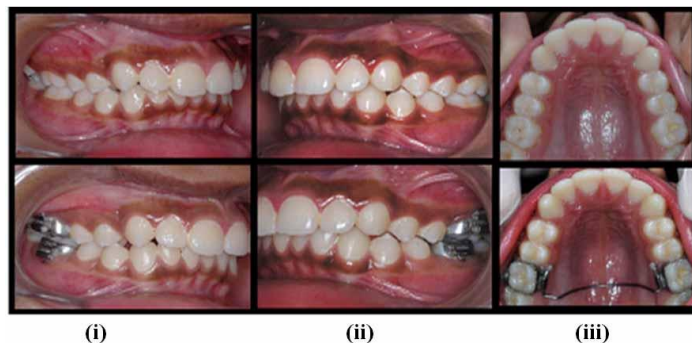
**Fig. 4: (i): Pre and post de-rotation right side molar relation changes from 3mm class II to full cusp class I. (ii) Pre and post de-rotation left side molar relation remains the same as class I. (iii) Pre and post maxillary occlusal view showing rotation correction of right first permanent molar.**

### Case 2: Bilateral Molar Rotation

A 13-year-old male patient presented with dentoalveolar Class II Division I subdivision malocclusion on Class II skeletal base with class I molar and canine relation on left and 3mm class II molar and canine on the right, with moderate lower anterior teeth crowding, and a mesial-in rotation of right and left maxillary first permanent molars. The patient was treated using Keles TPA, without loops

(Fig. 3 (ii)) to achieve de-rotations of maxillary first molars.

The appliance was activated on both right and left horizontal ends by 20 degrees each, followed by occlusal radiograph and impression, both before and after the correction. Bilateral molar de-rotation was achieved in 12 weeks with class I molar relationship established on both sides as shown (in Fig. 5).



**Fig. 5: (i): Pre and post de-rotation right side molar relation changes from 3mm class II to full cusp class I. (ii) Pre and post de-rotation left side molar relation remains the same as class I. (iii) Pre and post maxillary occlusal view showing bilateral molar de-rotation**

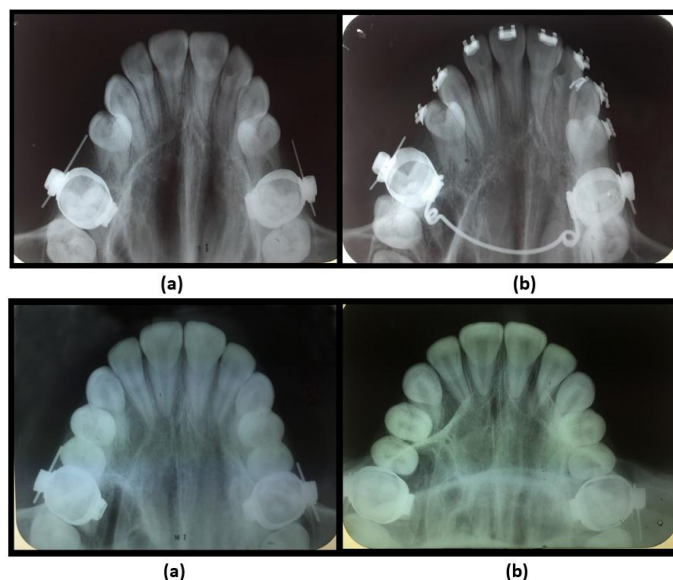
### Discussion

In case 1, de-rotation of the maxillary right permanent first molar significantly improved the molar relationship from 3 mm Class II to full cusp functional Class I. Class I molar and canine relationship on the left side was maintained. Similarly in case 2, Class I molar relationship was established on both sides.

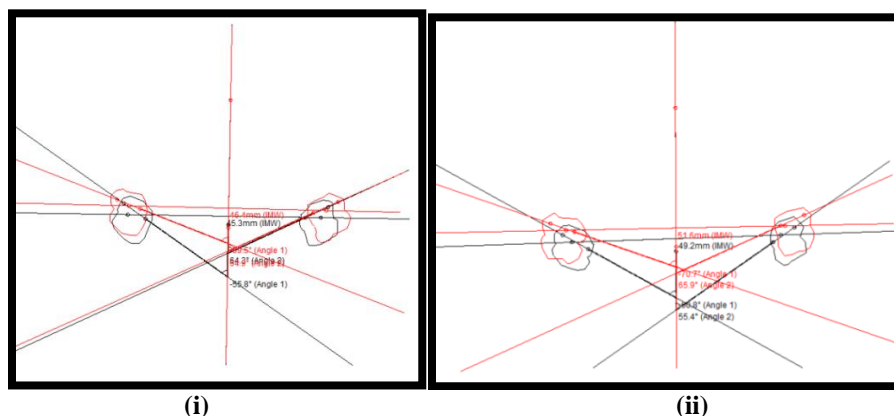
Pre and Post-treatment occlusal radiographs were compared by measuring the angle (Angle A) between the line passing along the radio-opaque marker in the maxillary first molars and median raphe.<sup>(6)</sup> In case 1, there was a decrease in the right side Angle A suggestive of de-rotation of the molar on the right side with no significant changes seen on the left side angulation. Whereas, in case 2 both right and left angles were decreased thereby correcting the rotation on both the sides. (Fig. 6 (i) & (ii))

The obtained result was confirmed by measuring the angle (Angle B) formed between the line passing through the mesio-buccal and mesio-palatal cusp tips of maxillary first molars and median raphe<sup>(7)</sup> in the photographed model of the maxillary cast assessed by Ilexis FACAD (AB-2014 version 3.8.00) software. The pre and post-treatment tracings were superimposed at the mid-palatine raphe where black ink represents pre-treatment tracings and red ink represents post-treatment tracings as shown in Fig. 7 (i) & (ii), where, Angle 1 is the right side angle and Angle 2 is the left single angle, IMW is the "Inter-molar Width".

Pre and post de-rotation values showed an increase in angle on the right side in case 1 and on both sides in case 2, confirming the de-rotation achieved. Inter-molar width showed no clinically significant changes in both cases, suggestive of minimal/no expansion.



**Fig. 6: (i): Case-1. a) Pre-treatment occlusal radiograph with marker wires in the tube slot. b) Post-derotation occlusal radiograph after 12 weeks where right molar is de-rotated with no changes in left molar. (ii): Case-2. a) Pre-treatment occlusal radiograph with marker wires in the buccal tube slot. b) Post-derotation occlusal radiograph after 12 weeks with bilateral rotation correction**



**Fig. 7: (i): Case-1. Superimposition in FACAD analysis: Superimposition showing marked increase in Angle 1 suggestive of right molar de-rotation and clinically insignificant changes in Angle 2 with a minimal increase in IMW. (ii): Case-2. Superimposition shows a clinically significant increase in both Angle 1 and 2 suggesting bilateral molar de-rotation with a mild increase in the IMW.**

## Conclusion

The Keles TPA resulted in a better transverse molar control during molar de-rotation owing to its superior self-locking design. When Keles TPA is used in correction of unilateral molar rotation, it causes successful de-rotation on the affected side and least or no changes on the unaffected side. Hence, Keles transpalatal arches can be used consistently to treat molar rotations with good clinical success.

## References

1. Andrews. L.: The six keys to normal occlusion, AJO. 62:296-309,1972.
2. Lamons.F.F and Holmes: The problem of rotated Maxillary First Molars, AJO. 47:246-272,1961.
3. Robert A. Goshgarian: Orthodontic palatal arch wires, US Patent 3,792,529,1974;1974.
4. Ahmet Keles and Sentef Impram: An Effective and Precise Method for Rapid Molar Derotation: Keles TPA, World J Orthod. 4:229-236,2003.
5. Charles J. Burststone: The Precision Lingual Arch: Hinge Cap Attachment, J. Clin. Orthod. 28(3):151-158, 1994.
6. Orton.H: An evaluation of five methods of derotating upper molar teeth, The Dental practitioner and Dental record. 16:279-286,1966.
7. Friel and Sheldon: Determination of the angle of rotation of the upper first permanent molar to the median raphe of the palate in different types of malocclusion, Dental Practitioner. 9:77-79,1959.