

## Co-existence of multiple pyogenic granuloma and intra oral lipoma in a 52 year old female patient- a rare entity

Alphy Alphonsa Sebastian<sup>1,\*</sup>, Hasan Subhi<sup>2</sup>

<sup>1</sup>PhD Student, Dept. of Oral Medicine & Oral Pathology, <sup>2</sup>PhD Candidate, Dept. of Conservative Dentistry, School of Dental Sciences, Universiti Sains Malaysia

**\*Corresponding Author:**

Email: alphyalphonsa1@gmail.com

### Abstract

Pyogenic granuloma is a reactive hyperplasia usually arises in the oral cavity secondary to low grade local irritation, traumatic injury, hormonal factors or certain kind of drugs. Lipoma is a benign tumor of adipose tissue, which constitutes 1-4% of all benign lesions. This paper presents the co-existence of pyogenic granuloma and intra oral lipoma on right buccal mucosa, both were managed by surgical intervention.

**Keywords:** Pyogenic granuloma, Lipoma, Excision, Hyperplasia, Hormonal factors

### Introduction

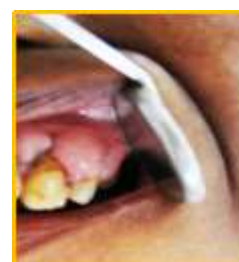Pyogenic granuloma is an inflammatory hyperplasia of the oral cavity, which is also known as Granuloma gravidarum. According to Robbins, granuloma is defined as a chronic inflammatory reaction containing a predominance of cells of macrophage series. It is a common tumor like growth of the oral cavity, which is considered to be the non-neoplastic in nature. It was originally thought to be caused by pyogenic organisms. It is now believed to be unrelated to infection. It represents an exuberant tissue response to local irritation or trauma.<sup>(1)</sup> Lipoma is the most common tumor which occurs in trunks and extremities. The rare occurrence of lipoma is already noted in the oral cavity.<sup>(2)</sup> We report a case of intra oral lipoma in right buccal mucosa and pyogenic granuloma which co-exists in the same patient.

### Case Report

A 52 year old female patient reported to oral medicine and radiology department, with the chief complaint of growth with respect to upper right and left back teeth region since 3 years. History of presenting illness showed that patient noticed the growth 3 years back which was initially small in size and gradually increased to the present size. Moreover, the growth was associated with pain and also occasional bleeding on chewing hard food. Patient also revealed another painless slowly growing mass in the right cheek region since last three years. Medical history revealed that she attained menopause five years back. She was a known diabetic for past two years and on medication.

Intra oral examination revealed a solitary, pedunculated growth in the labial gingiva between 23, 24,25 (Fig. 1), and 13, 14 (Fig. 2) region, which was attached to interdental papilla measuring approximately 1.5cm x1.2cm in size. The surface was smooth, appeared pink in color which bleeds on probing when 36 and 37 impinges on the growth. When teeth are brought in occlusion in palpation, growth is non-tender, firm in

consistency and bleeds on probing. Also, lesion on right buccal mucosa (Fig. 3) was solitary, soft tissue mass, 2x 0.9cm in size, with smooth margins and was not fixed to underlying deep structure. Generalized inflammation of gingiva and calculus present was double positive. Considering all the above features, a provisional diagnosis of pyogenic granuloma was given and the differential diagnosis included peripheral giant cell granuloma, irritational fibroma, peripheral ossifying fibroma and peripheral ameloblastoma. All the blood parameters were within normal limits except the random blood sugar which was 308mg/dl. The treatment included oral prophylaxis and an excisional biopsy for both lesions. Histopathological examination showed parakeratinized stratified squamous epithelium with numerous blood vessels suggested pyogenic granuloma (Fig. 4). Histopathological examination of swelling of right buccal mucosa revealed adipocytes with respect to eccentric nucleus and clear cytoplasm (Fig. 5), suggestive of lipoma. When the patient was reviewed after one week, mucosa healed uneventfully. There was no recurrence even at the end of one year.



**Fig. 1**

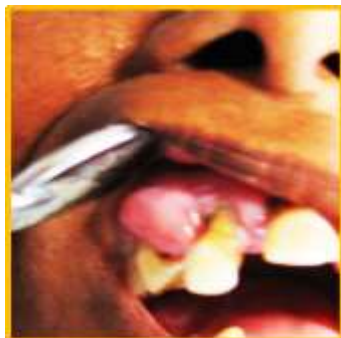

Fig. 2

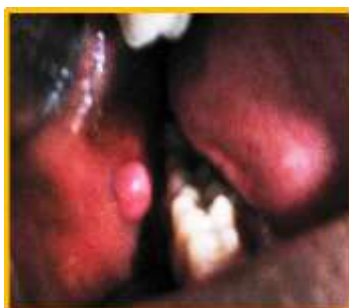

Fig. 3

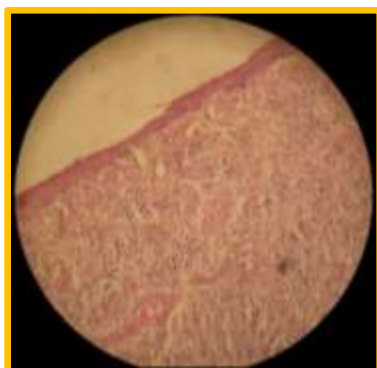


Fig. 4



Fig. 5

## Discussion

Pyogenic granuloma occurs in tissue as a response to various stimuli such as low-grade chronic irritation, trauma and hormonal imbalance.<sup>(3)</sup> The various synonyms for pyogenic granuloma are Crocker and Hartzell's disease, granuloma pyogenicum, granuloma pediculatum benignum, benign vascular tumor and

during pregnancy as granuloma gravidarum.<sup>(4)</sup> In 1844, Hullihen discovered the foremost case of pyogenic granuloma in English literature.<sup>(5)</sup> This lesion was designated as botryomycosis hominis by Poncet and Dor in 1897. The pioneer Hartzell in 1904, coined the term pyogenic granuloma.<sup>(4)</sup> This lesion constitutes on an average of 29.4% of all reactive hyperplasia lesion.<sup>(6,7)</sup> The incidence of this lesion is maximum in females of third decade. Based on the scientific evidence, estrogen can trigger nerve growth factor, fibroblast growth factor, Granulocyte macrophage-colony stimulating factor which ultimately forms granulation tissue.<sup>(6,7,8)</sup> Majority of the lesions (75%) of lesions occurs in interdental papillae, followed by lower lip, tongue, palate and buccal mucosa.<sup>(9)</sup> The clinical presentation is usually as a pedunculated smooth or lobulated warty mass, color ranges from pink to red purple.<sup>(10,11,12)</sup> It is painless and soft in consistency, although older lesions tend to be firm and fibrate. This was consistent with the features of pyogenic granuloma in present case. In these case as the patient attained 52 years old, hormonal imbalance could be the main etiological factor for the lesion to occur. It has been stated that young lesions are more pinkish and hemorrhagic. On the contrary, older lesions are pale and collagenized.<sup>(8)</sup> The present case, lesion showed similar color of adjacent mucosa. The only treatment modality is surgical excision. But the most common complication after surgical excision is the recurrence rate. It was noted that for this lesion, the rate is 20%.

The first description of lipoma was given by Roux in 1848, where he referred it as "yellow epulis" in the alveolar mucosa.<sup>(13)</sup> Most of the cases, the etiology is unknown. But the possible etiological factors are trauma, infection, chronic irritation, infection, hormonal alterations and chromosomal aberrations. In head and neck region, the syndromes associated with multiple lipomas are Gardners and proteus syndrome. Lipoma is clinically presented as slow growing mass with mean size 20mm that has been developing for several years, as observed in the present situation.<sup>(14)</sup> Usually, the lesion may present as well defined, fluctuant solitary or multiple yellowish nodules. The differential diagnosis of lipoma includes, oral dermoid<sup>(15)</sup> and lymphoepithelial cyst. The features that differs lymphoepithelial cyst from lipoma is based upon the smaller size, the occurrence of this lesion in soft palate, pharyngeal tonsil and early age of occurrence (10-30 years).<sup>(16)</sup> Histopathologically lipoma is categorized into fibrolipoma, intramuscular lipoma, angio lipoma, myxoid lipoma, spindle cell lipoma, pleomorphic lipoma and osteolipoma. lipoma with fibrous connective tissue are fibrous lipoma; lipoma located within striated muscles are infiltrating or intramuscular lipoma;<sup>(17,18)</sup> lipoma with excess blood vessels are angiolipoma; lipoma with myxoid background are myxoid lipoma; lipoma with spindle shaped cells are spindle cell lipoma; lipoma with dysplastic spindle cells with enlarged nuclei are pleomorphic lipoma.<sup>(2,5)</sup> In all these variants, the

treatment option is only surgical excision. No recurrence has been reported. In this case, no recurrence was observed.

### Conclusion

As part of early intervention, multiple lipomas of head neck have been diagnosed, as those multiplicity of lesions would be a part of systemic diseases such as neurofibromatosis, gardner syndrome, proteus syndrome and multiple familial lipomatosis. So due consideration should be given for correct diagnosis and proper treatment planning. As the recurrence rate of pyogenic granuloma is 16%, careful management of the lesion helps in preventing the recurrence of this lesion.

### Acknowledgement

The work was supported by USM Global Fellowship from Universiti Sains Malaysia.

### References

1. Ramirez. K, Bruce G: carpenter. Pyogenic granuloma: case report in a 9-year-old girl. *General Dentistry*. 2002,50(3): 280-1.
2. Neville BW, Damm DD, Allen CM, Bouquot JE: oral and maxillofacial pathology. 2004, W.B. saunders co, 444-449.
3. Karthikeya Patil, mahima VG, Lahari K: Extragingival pyogenic granuloma. *Indian journal of dental research*. 2006,17(4):199-202.
4. Hüllihen SP (1844) Case of aneurism by anastomosis of the superior maxillae. *Am J Dent Sci* 4:160-162.
5. Gnepp DR. 1st ed. Philadelphia: Saunders; 2010. *Diagnostic Surgical Pathology of the Head and Neck*; p. 192.
6. Amirchaghmaghi M, Falaki F, Mohtasham N, Mozafari PM (2008) Extragingival pyogenic granuloma: a case report. *Cases J* 1: 371.
7. K A K, Ashok L, G P S (2013) Pyogenic granuloma on the upper labial mucosa: a case report. *J Clin Diagn Res* 7:1244-1246.
8. Jafarzadeh H, Sanatkhani M, Mohtasham N (2006) Oral pyogenic granuloma: a review. *J Oral Sci* 48:167-175.
9. Regezi JA, sciubba, James J, Jordan Richors CK: *Oral Pathology, clinical pathologic correlation*. 2003, Sanders Company, 115-76.
10. Akyol MU, Yalciner EG, Dolan AI: Pyogenic granuloma (lobular capillary hemangioma) of the tongue. *Int J Pediatr Otorhinolaryngol*. 2001,58 (3):239-241.
11. Greenberg MS, Glick M: *Burket's oral medicine Diagnosis & treatment*. 2003, B C Decker Inc, 141-142. Tenth edition.
12. Cawson RA, Odell EW: *Cawson's essentials of oral pathology and medicine*. 2002, Churchill Livingstone, 277-7.
13. R. Rajendran and B. Sivapathasundharam, Shafer's *Textbook of Oral Pathology*, Elsevier, India, 5th edition, 2009.
14. Chidzonga MM, Mahomva L, Marimo C. Gigantic tongue lipoma: a case report. *Med Oral Patol Oral Cir Bucal*. 2006;11(5):E437-9.
15. Anavi Y, Gross M, Calderon S. Disturbed lower denture stability due to lipoma in the floor of the mouth. *J Oral Rehabil*. 1995;22(1):83-5.
16. Flaitz CM. Oral lymphoepithelial cyst in a young child. *Pediatr Dent*. 2000;22(5):422-3.
17. Lawoyin JO, Akande OO, Kolude B, Agbaje JO. Lipoma of the oral cavity: clinicopathological review of seven cases from Ibadan. *Niger J Med*. 2001;10(4):189-91.
18. Fregnani ER, Pires FR, Falzoni R, Lopes MA, Vargas PA. Lipomas of the oral cavity: clinical findings, histological classification and proliferative activity of 46 cases. *Int J Oral Maxillofac Surg*. 2003;32(1):49-53.