

The contribution of collagen matrix in apexification with MM-MTA®

Nesrine TEBBEB^{1,*}, Ehsen ABDELMOUMEN², Sonia ZOUITEN³, Imen GNABA⁴, Abdelatif BOUGHZELA⁵

¹PG Student, ³Professor, ⁴Assistant Professor, ⁵Professor, Chief Department, Dept. of Dental Medicine, Dept. of Conservative Dentistry & Endodontics, EPS Farhat Hached-Sousse, Tunisia, ²Assistant Professor, Dept. of Conservative Dentistry & Endodontics, Faculty of Dentistry of Monastir, Tunisia

***Corresponding Author:**

Email: nesrinetebbeb@hotmail.fr

Abstract

The absence of an apical constriction and the divergent apical architecture of the root canal hamper complete debridement, canal disinfection and obturation. In the past, calcium hydroxide was currently used to create a root- end barrier, but there are some disadvantages. Since its invention, the MTA has been popularized in endodontic because of its excellent properties.

This article presents a detailed case report of the use of a collagenic matrix prior to placement of MTA as an apical barrier and a second case without the use of the matrix.

Keywords: MTA, Matrix collagenic, Apexification, Open apice

Introduction

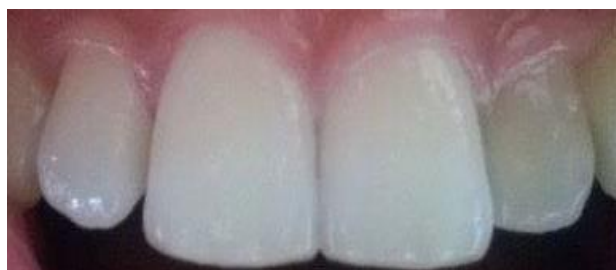Immature teeth with open foramina present the challenge to obtain the main objective of all endodontic procedures which is a hermetic seal between the periodontium and root canal foramina. The absence of an apical constriction and the divergent apical architecture of the root canal hamper complete debridement, canal disinfection and obturation. In the past, calcium hydroxide was currently used to create a root- end barrier, but there are some disadvantages such as an increase number of appointments and radiographs, possibility of fracture after calcium hydroxide use for long periods. Also, it is difficult to follow-up the patient because of the delayed treatment.

Since its invention by Mahmoud Torabinejed and colleagues in 1993, the MTA has been popularized in endodontic because of its excellent properties in terms of biocompatibility, sealing ability, dentinogenic and osteogenic potential, inducing cementum apposition and regeneration of periodontal ligament. It has a lot of indications in dentistry, one of them is apexification.⁽⁴⁾ In 1992, Lemon advocated the use of a matrix when the perforation diameter is larger than 1 mm to avoid extrusion of the sealing material.⁽⁶⁾ The use of a matrix is advisable since its placement in the area of bone destruction provides a base on which the sealing material, especially MTA, can be placed and packed in the perforation.^(6,7) Several materials have been recommended to create a matrix, in cases of perforations as well as teeth with incomplete formation of apex; including calcium hydroxide, hydroxyapatite, resorbable collagen and calcium sulfate.^(8,9)

This article presents a detailed case report of the use of a collagenic matrix prior to placement of MTA as an apical barrier and a second case without the use of the matrix.

Case Report

Case 1: A 27-year-old girl with a non-contributory medical and familial history consults our department of dentistry with a recurrent abscess and fistula in her upper left vestibule. Clinical examination revealed discolored upper left lateral incisor (Fig. 1).



**Fig. 1: Clinical view
(discolored upper left lateral incisor)**

Radiological examination revealed that this tooth presented an invagination type II (Classification of Oehlers), large periapical radiolucency, incomplete root development and an open apice. (Fig. 2, 3, 4). A Cone Beam Computed Tomography was advised which showed the exact size of the periapical lesion especially the destruction of the palatal cortical bone. (Fig. 5, 6, 7, 8, 9) The decision was debridement and root canal preparation. Rubber dam was placed. The access cavity was opened. Because the canal was very large, we used stainless steel K-file number 50, 55 and 60. Irrigation with 2.5% sodium hypochlorite was done. The working length was measured radiographically and recorded for reference. The canal was filled with calcium hydroxide paste (Metapaste, Meta-Biomed) and the access cavity was temporary sealed with Cavit (3M ESPE AG, Seefeld, Germany) (Fig. 10). The patient returned with a cellulitis, we opened the tooth to drain and prescribed an antibiotic. Two days later, the tooth was disinfected

and filled with the calcium hydroxide. After ten days, she returned with the same symptoms and had a cellulitis for a second time. Because she suffered from a recurrent cellulitis, our decision was to create, the apical plug, to obturate the rest of the canal with Gutta Percha and to enucleate the periapical lesion with surgery.

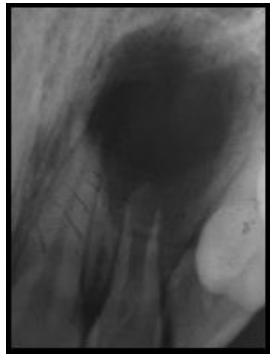


Fig. 2

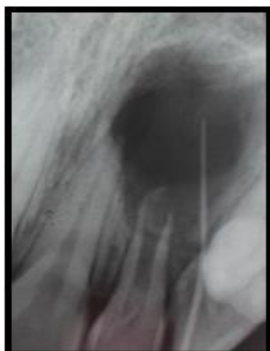


Fig. 3

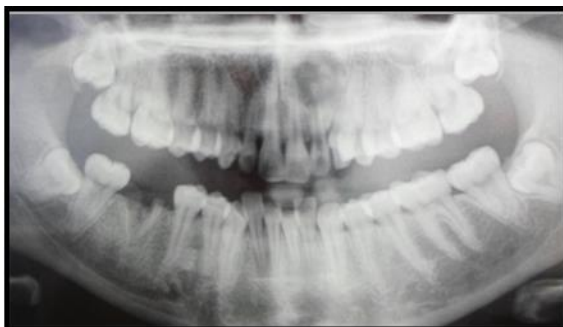


Fig. 4

Fig. 2-4: Radiological examination:an invagination type II (Classification of Oehlers), large periapical radiolucency, incomplete root development and an open apice

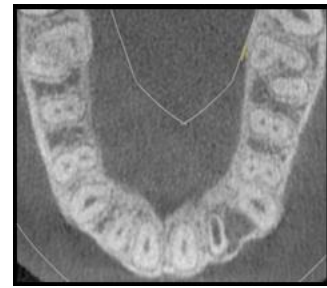

Fig. 5

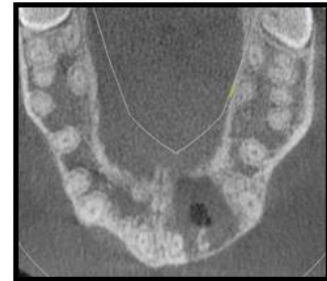

Fig.6

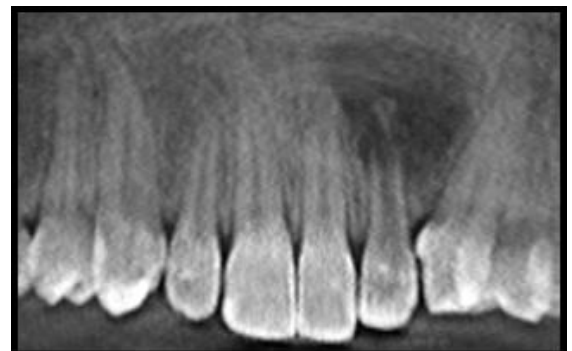


Fig. 7

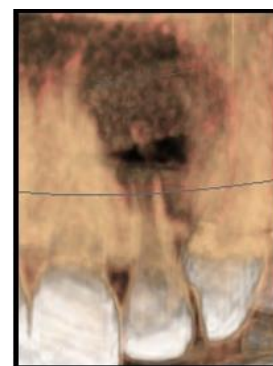


Fig. 8

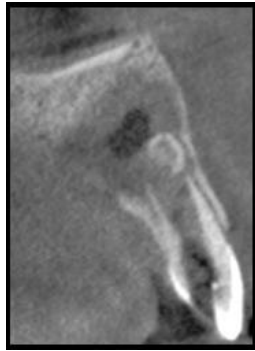**Fig. 9**

Fig. 5-9: Cone Beam Computed Tomography: Destruction of the palatal cortical bone

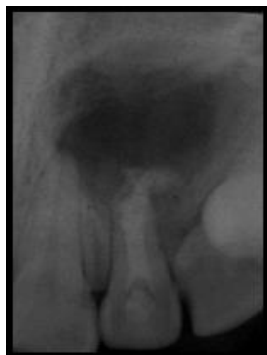

Fig. 10: The canal was filled with calcium hydroxide paste (Metapaste, Meta-Biomed) & the access cavity was temporary sealed with Cavit (3M ESPE AG, Seefeld, Germany)

Small pieces of ETIK collagen (Acteon Pierre Roland) were packed against the bone into the periapical defect in order to create a matrix for the placement of MMTA (MicroMega). The MMTA was compacted against the barrier with pluggers to create an apical plug approximately 4 mm thickness. The rest of the canal was filled with flowble Gutta Percha (system QUIRLESS) and the coronal cavity was sealed with Cavit (3M ESPE AG, Seefeld, Germany). A radiograph confirms the obturation of the totality of the canal. (Fig. 11)

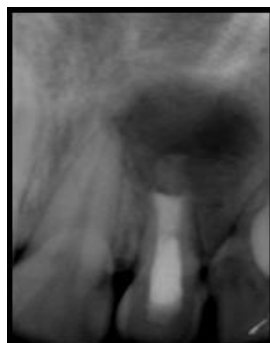

Fig. 11: An apical plug approximately 4mm thickness & obturation of the rest of the canal with gutta percha

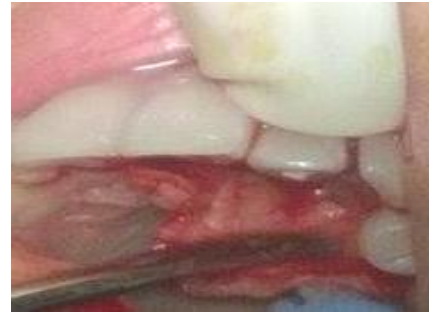

Fig. 12: The flap tissues & periosteum were retracted (full-thickness flap) The bone was exposed

The enucleating surgery of the cyst was successfully done the next day. Under local anesthesia an incision was performed using a scalpel blade number 15 in the palatal aspect of the anterior maxillary region in between teeth number 11 and number 25 (Fig. 12).

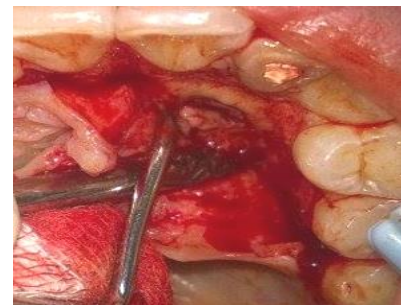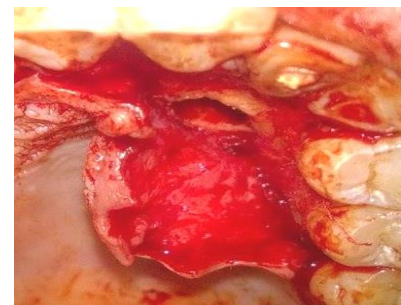**Fig. 13****Fig. 14**

Fig. 13, 14: Soft tissues attached in the internal surface of the flap corresponding to the cystic lesion was collected

Then, the flap tissues and periosteum were retracted (full-thickness flap), and the bone exposed. The soft tissues attached in the internal surface corresponding to the cystic lesion was collected (Fig. 13, 14), but we noticed there is more infected tissues attached to the buccal cortical bone so another full-thickness flap was done between teeth number 21 and number 23 (Fig. 15). Using a low speed 0.8cm trephine, a circular osteotomy was performed and the rest of the tissues was enucleated (Fig. 16, 17). A communication between the two bone defects was noticed (Fig. 18). We could see

the MTA on the top of the root.(Fig. 19) At the end, the two flaps were sutured. The patient was informed that the control is important. The follow up was done after three (Fig. 21), six (Fig. 22) and twelve (Fig. 23) months and demonstrated a radiographic decrease in the periapical radiolucency. The tooth was asymptomatic and clinically functional.

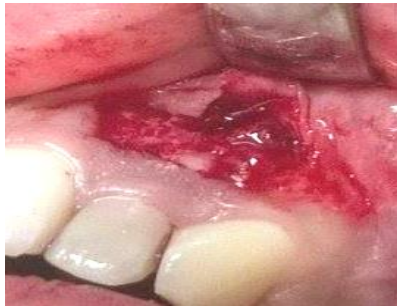

Fig. 15: The second full-thickness flap



Fig. 16, 17: The rest of the tissues was enucleated

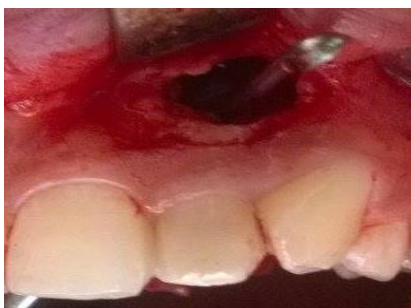
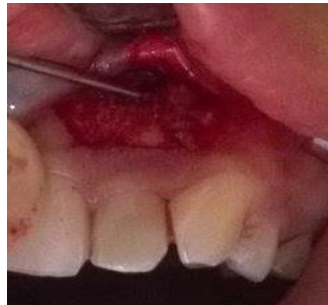
Fig. 18: A communication between the two bone defects was noticed

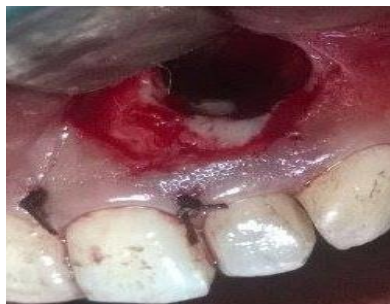

Fig. 19: Clinical view of the plug of the MTA

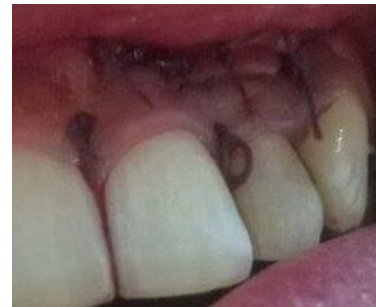

Fig. 20: The flap was sutured

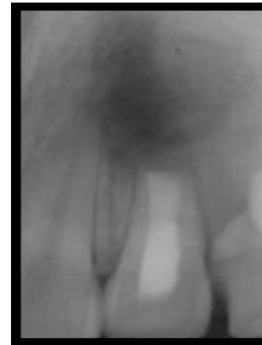

Fig. 21: 3months follow-up

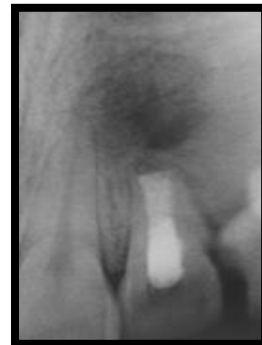

Fig. 22: 6months follow-up

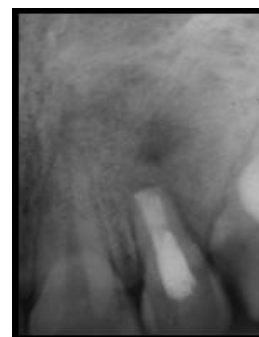

Fig. 23: 12months follow-up

Case 2: A girl aged 9 years, reported to our dental department with history of traumatic injuries to maxillary central incisors. The teeth were diagnosed to be non-vital with a combination of clinical signs, vitality tests and radiographs. It had an open apice and periapical radiolucency. (Fig. 24) The teeth were

isolated with rubber dam. Access cavity was prepared in the palatal surface of the incisors. The canal was then gently cleaned with manual instruments of the root apex with 2.5% sodium hypochlorite irrigation. The working length was measured radiographically (Fig. 25) and recorded for reference. The canal was dried with sterile paper points and filled with calcium hydroxide and the access cavity was sealed with Cavit.

MMTA plug was placed in the canal with a carrier and pluggers, sized according to the apical diameter were used to condense the material to form apical plug with a thickness of approximately 4 mm. Unfortunately, the MTA was extruded in the bone defect due to the periapical lesion. The rest of the canal was obturate with Guta Percha and the access cavity was filled with composite.(Fig. 26)

The mother of patient was informed about the extrusion. The follow up demonstrated that the patient functioning well with no reportable clinical symptoms and the radiograph after one year showed that the periapical lesion is on going healing.(Fig. 27)

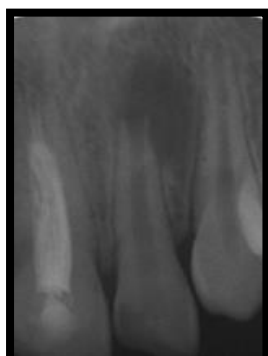

Fig. 24: Preoperative radiograph: an open apex & periapical radiolucency

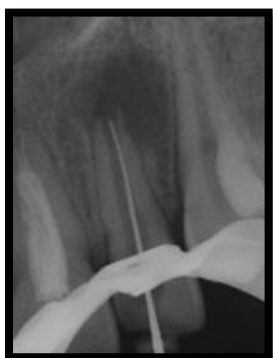

Fig. 25: Working length radiograph

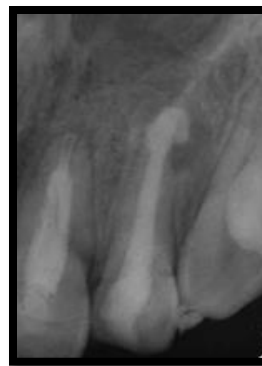

Fig. 26: Post-operative radiograph: extruded MTA on the periapical lesion

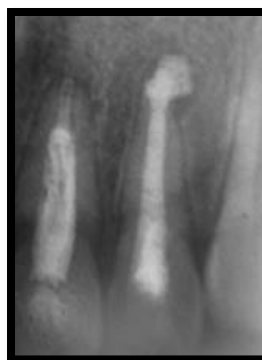

Fig. 27: 12 months follow-up

Discussion

A number of methods have been recommended for artificial apical closure. For a long time, calcium hydroxide has been used as an apexification material. The newly developed MTA has also been shown to be effective in artificial root-end closure.⁽¹⁾

A study comparing the effectiveness of Ca(OH)₂ versus MTA has shown that MTA has been found to be as effective as Ca(OH)₂ for the treatment of cases with an open apex. MTA has shown to be effective in performing the same procedure in a considerably lesser period of time with predictable results. The authors also concluded that the chances for biological calcific bridge formation are favorable when the root canal apices are flush or underfilled with MTA.⁽¹⁴⁾

MTA, a bio-compatible material, can be used to create a physical barrier that also helps in formation of bone and periodontium around its interface. The application of MTA immediately after root canal preparation favored the establishment of a normal periodontal ligament and formation of new bone and cementum. The stimulatory effect of MTA on the biosynthetic activity of periradicular cells. Hard tissue formation seems to be activated progressively from the peripheral root walls to the centre of the MTA. When used in root-end cavities stimulate reparation of periradicular tissues. The nature of formative cells and newly formed hard tissue, as well as the mechanism

controlling MTA-activated hard tissue formation, needs to be investigated further.⁽¹⁹⁾

The major problem in cases of a wide open apex is the need to limit the material to working length, thus avoiding the extrusion of a large amount of material into the periodontal tissue.

A large volume of the extruded material may set before it disintegrates and get resorbed. This might result in the persistence of the inflammatory process, which may complicate or even prevent repair of the tissue.^(11,12) Lemon (1992) introduced the "internal matrix concept" for treatment of root perforations. He recommended careful placement of hydroxyapatite through the perforation to form an external barrier and matrix, against which the perforation repair material (amalgam) was condensed. Bargholz (2005) gave the modified internal matrix concept; he recommended the use of collagen as a completely resorbable barrier material and MTA as a perforation repair material. The repair of perforation requires a matrix to control the repair material. The same concept is utilized for the placement of MTA apical barrier in immature teeth

Using a matrix avoids the extrusion of the material into the periodontal tissues, reduces leakage in the sealing material and allows favorable response of the periodontal tissues.⁽¹⁾

Using a matrix will restrict the barrier material at the apex and prevent the extrusion of material into the periodontal tissues. Various materials used as a matrix are calcium hydroxide, hydroxyapatite, collagen, calcium phosphate⁽¹⁷⁾ tricalcium sulfate⁽¹⁶⁾ and PRF (immune platelet concentrate).⁽¹⁵⁾

Absorbable Collagen Haemostatic Sponge, in addition to their property of absorbability, possess multiple characteristics: soft, white, pliable, non-friable, coherent and sponge-like structures,⁽¹³⁾ a weak immunogenic and well tolerated by the tissues.⁽²⁾ They are fabricated from bovine collagen (usually from deep flexor tendons) and are nontoxic and non-pyrogenic. The products are highly absorbent and able to hold many times their own weight of fluid. They may be cut to shape and applied to a bleeding surface. When placed, they rapidly absorb blood, creating an artificial clot-like structure, thereby slowing or stopping bleeding at the site. These collagen materials completely resorb within 14 to 56 days, depending on how cross-linked the material is.⁽¹³⁾ The collagen barrier not only prevented the extrusion of the MTA apical plug but also prevented the contact of MTA with tissue fluids and blood during plug insertion.⁽²¹⁾

Barriers help produce a dry field and provide an internal matrix or "back stop" against which to condense restorative materials, as well as a good apical seal with MTA in teeth with blunderbuss apices.⁽³⁾ Because it was difficult to achieve satisfactory restoration of the apical portions through the access cavity, the extra-radicular barrier permitted dense packing of the MTA in close proximity to the apexes.⁽⁵⁾

To prevent overfilling with MTA, the clinician placed a collagen membrane through the apex to provide an extra-radicular barrier against which the MTA could be packed. The barrier may make the use of MTA easier, and it also may control bleeding and extrusion of the filling material.

Following extrusion of MTA into the peri-radicular tissues, osseous healing and resorption of MTA might occur, or it may remain unset and affect the healing process. The physical irritation of the oral mucosa after MTA extrusion is another possibility when the set material becomes sandwiched between the bone and mucosa. The outcome of treatment after extrusion of MTA into the peri-radicular tissues is unpredictable. More histological studies on tissue reactions to unset MTA, the effects of unset MTA on the healing process and the effects of set MTA on soft peri-radicular tissues are recommended.⁽²⁰⁾

Recently, new promising concepts aiming at revascularization of the necrotic pulp of such teeth have been advocated. In the past months, a number of case reports and a clinical pilot study have been published. Revascularization has been considered to be a better option for dealing with immature teeth with non-vital pulp and even for cases with severe periapical infection. This alternative method seems to have the potential for increasing root length and thickness of root canal walls of non-vital immature teeth, with the help of blood clotting and a collagen-enhanced matrix. From this perspective it has been recently proposed that apexification might no longer be needed in the near future. Nevertheless, controlled clinical studies are warranted to demonstrate that the revascularization method can replace the established treatment protocols based on calcium hydroxide or MTA.⁽⁴⁾

Conclusion

The combination of a collagenic matrix and MTA has been demonstrated to be a good option for creating artificial root end barrier. The placement of MTA is predictable and easily achieves and the outcomes are very encouraging

References

1. Roheet A Khatavkar, Vivek S Hegde. Use of a matrix for apexification procedure with mineral trioxide aggregate, *J Conserv Dent.* 2010 Jan-Mar; 13(1):54-57.
2. Johns LP, Merrit K, Agarwal S., Immunogenicity of a bovine collagen membrane used in guided tissue regeneration. *J Dent Res* 1992;71(special issue):298-301.
3. Ingle JJ, Bakland LK, Baumgartner JC. *Ingle's Endodontics* 6. 6th ed. Hamilton, Ontario, Canada: Decker; 2008:1130.
4. Robotta P. Mineral Trioxide Aggregate for Obturation of non-vital maxillary central incisors with open apices after trauma. *ENDO (LondEngl)*. 2011;5(1):53-61.
5. Cases, Vanka A, Ravi K S, Shashikiran N D, Apexification with MTA using Internal Matrix: Report of 2, *J Clin Pediatr Dent* 34(3):197-200, 2010.

6. Lemon RR. Nonsurgical repair of furcal perforations with defects. *Dent Clin North Am* 1992;36:349-457.
7. Bargholz C. Perforation repair with mineral trioxide aggregate: A modified matrix concept. *Int Endod J* 2005;38:59-69.
8. Roheet A, Khatavkar and Vivek S Hegde, Contaminated furcal perforation in dogs teeth repaired by MTA with or without internal matrix. *Oral Surg Oral Med Oral Pathol Oral Radiol Endod* 2007;103:92-9.
9. Zou *Let al.* Effect of placement of calcium sulphate when used for repair of furcation perforation on seal produced by a resin-based material. *Int Endod J* 2007;40:100-5.
10. Holden DT, Schwartz SA, Kirkpatrick TC, Schindler WG. Clinical outcomes of artificial root-end barriers with mineral trioxide aggregate in teeth with immature apices. *J Endod* 2008;34:7:812-7.
11. Broon NJ *et al.* Healing of root perforations treated with mineral trioxide aggregate (MTA) and Portland cement. *J Appl Oral Sci* 2006;14:305-11.
12. Holland R, Mazuqueli L, Souza V, Murata SS, Dezan E Jr. Influence of the type of vehicle and limit of obturation on apical and periapical tissue response in dogs teeth after root canal filling with mineral trioxide aggregate. *J Endod* 2007;33:693-7.
13. Mahesh L, Kurtzman GM, Shukla S, Regeneration in Periodontics: Collagen-A Review of Its Properties and Applications in Dentistry. *Compend Contin Educ Dent*,2015May;36(5):358-63.
14. Pradhan DP, Chawla HS, Gauba K, Goyal A. Comparative evaluation of endodontic management of teeth with unformed apices with mineral trioxide aggregate and calcium hydroxide. *J Dent Child (Chic)*. 2006;73(2):79-85.
15. Anisha Kumar, Amit Yadav, Neeta Shetty, One-step apexification using platelet rich fibrin matrix and mineral trioxide aggregate apical barrier, *Indian Journal of dental research*,2014;25(6):809-12.
16. Coviello J, Brilliant JD. A preliminary clinical study on the use of tricalciumphosphate as an apical barrier. *J Endod*. 1979;5:6-13.
17. Nevins A, Finkelstein F, Laporta R, Borden BG Induction of hardtissue into pulpless open-apex teeth using collagen-calcium phosphategel. *J Endod*. 1978;4:76-81.
18. W. T. Felipe, M. C. S. Felipe and M. J. C. Rocha. The effect of mineral trioxide aggregate on the apexification and periapical healing of teeth within complete root formation. *Inter Endo J*,2006;36(1):2-9.
19. N. Economides, O. Pantelidou, A. Kokkas & D. Tziafas. Short-term peri-radicular tissue response to mineral trioxide aggregate (MTA) as root-end filling. *Inter Endo J*,2003;36(1):44-48.
20. A. Nosrat, M. H. Nekoofar, B. Bolharim & P. M. H. Dummer. Unintentional extrusion of mineral trioxide aggregate: a report of three cases. *Inter Endo J*,2012;45(12):1165-76.
21. Gharechahi M, Ghodduzi. A nonsurgical endodontic treatment in open-apex and immature teeth affected by dens invaginatus: using a collagen membrane as an apical barrier. *Journal of the American Dental Association*, 2012;143(2), 144-8.