

Spatial evaluation of Mental Foramen among UAE locals attending UDHS using CBCT

Mohammed Hussain Al-Zainal^{1,*}, Shamim Faraghat², Hassan Abdulqader³, Maryam Al-Emadi⁴, Youssef Marquise⁵, Natheer Al-Rawi⁶

^{1,2,3,4,5,6}College of Dental Medicine, University of Sharjah, UAE

***Corresponding Author:**

Email: hussainhaider@windowlive.com

Abstract

Aim: Mental foramen could be an area subjected to trauma due to surgery or implant placement in mental area. Our aim is to measure the different parameters of the mental foramina of males and females among UAE Nationals visiting the University Dental Hospital Sharjah to enhance our knowledge of the possible locations of the mental foramen in order to prevent iatrogenic injuries through periodontal and endodontic surgeries, local anesthesia and implant placement.

Materials and Methods: This study was a retrospective study and samples included in the study were UAE nationals who already underwent a CBCT examination in the University Dental Hospital Sharjah in the period of 2010 till 2015. All samples were for nationals of the United Arab Emirates between the age of 18 and 65 whose CBCT scans shows the mental foramen area and the adjacent teeth (lower canines and first molars). Parameters measured in the mental foramen included height of foramen, width of foramen, shortest distance from foramen to adjacent tooth.

Results: There was a statistically significant gender difference between the mean value of mental foramen height (3.77 mm±0.86 mm for males) and 3.10 mm ± 0.8mm for females) (P = 0.002). The shortest distance of the foramen to the adjacent tooth also showed statistically significant gender differences (4.68mm ± 3.23mm for males) and (4.71 mm±1.94 mm for females), f (p= 0.012).

Conclusion: The height of the foramen and the distance of MF to the most adjacent tooth were greater in UAE males than in females. Discrepancy in the height of the foramen when dealing with different ethnicities should be taken into consideration.

Clinical Significance: MF is an important anatomical landmark for dental surgeons performing periapical surgery in the mental region such as endodontic and periodontal procedures. In order to avoid any nerve damage during oral surgery, MF location should be identified while keeping in mind the possibility of an anterior loop of the mental nerve being present mesial to the mental foramen. This should also be noted whilst performing surgery for implant placement.

Keywords: CBCT, Mental foramen, UAE nationals, Implants, Anatomical variations.

Introduction

The mental foramen (MF) is located on the antero-lateral aspect of the body of the mandible between the inferior and superior borders.⁽¹⁾ The mental nerve and vessels pass through this foramen. The mental nerve is a somatic afferent sensory branch of the alveolar inferior nerve and it divides into 4 branches: the angular, the medial, the lateral inferior labial branches and the mental branch.⁽²⁾ They provide sensation to the anterior aspect of the chin, lower lip and buccal gingiva of the mandibular anterior teeth and premolars. Thus, it is a vital structure in procedures such as administration of local anesthesia and surgery.

Conventional radiographs can usually be used for dental procedures. However, if it is complicated to locate the inferior alveolar canal or the mental foramen, consideration should be given to obtain a radiographic image using three dimensional reconstruction from cone beam computed tomography (CBCT). CBCT is the most accurate technology due to its high resolution and high reliability in identification of craniofacial structures. It also allows for multiple imaging post-process protocols to achieve a better treatment plan or evaluation.⁽³⁾

In addition to its significance in endodontic and periodontal procedures, the Mental Foramen plays an important role in the fields of anesthesia and oral surgery as well. In anesthesia, though it is possible to identify the mental foramen by palpation and by radiograph, knowing the normal range of possible locations in different ethnic groups and genders will help reduce the risk of iatrogenic accidents, thereby providing a much safer procedure.⁽⁶⁾ On the other hand, mental foramen which gives off the mental nerve is susceptible to damage during dental implant procedures involving the mandible,⁽⁷⁾ resulting in numbness, pain, or altered sensation.⁽⁸⁾ The aim of this study is to evaluate the position of mental foramina in males and females UAE Nationals. In order to have an idea about the location & inclination of the mental foramen course to prevent possible injuries during surgeries, anesthesia and implant placement.

Materials and Methods

Subjects: This study was a retrospective study and samples included only UAE nationals who already underwent a CBCT examination in the University Dental Hospital Sharjah from the period of 2010 till 2015. (The estimated sample size was 60 patient which

was calculated using exact test with independent variable formula the assuming effect size to be = 0.4, the α -error probability = 0.5 and power of study = 95%. Therefore, the sample was adjusted to 66 subjects (28males and 38 females) to compensate for the cases excluded All samples were UAE nationals between the age of 18 and 65 whose CBCT scans shows the mental foramen area and the adjacent teeth (lower canines and first molars). Cases excluded from study include subjects with trauma, skeletal asymmetries, or any destructive bone disease. Moreover, buccal foramina showing discontinuity with the mandibular canal and scans with extensive/severe radiographic artifacts were also excluded.

Data acquisition: The CBCT scans were taken by the Sirona Dental Systems/ GALILEOS using the following acquisition protocol: 85 kVp, 7 mAs, volume elements measuring 512x512x512 (volume elements),

and a 0.3 mm³ voxel resolution. After image acquisition, the data were stored in a digital imaging communication in medicine (DICOM) file format and imported to an DV6 windows independent workstation (HP 8) with DICOM viewer Galileos Viewer 1.9 (Sirona Dental Systems, Inc., Fabrikstrasse 31, 64625 Bensheim, Germany; www.sirona.com). Galileos Viewer software can be used to view volumetric images that capture, store, communicates, process and display DICOM (dcm file) images. GALAXIS was used to generate 3D reconstructed images.

Measurement parameters: Parameters measured in the mental foramen included height of foramen, width of foramen, shortest distance from foramen to adjacent tooth. Angulation of mental canal in the coronal view, distance from foramen to lower border of mandible, angulation of mental canal in the axial view, **as seen in Fig. 1 and Fig. 2)**

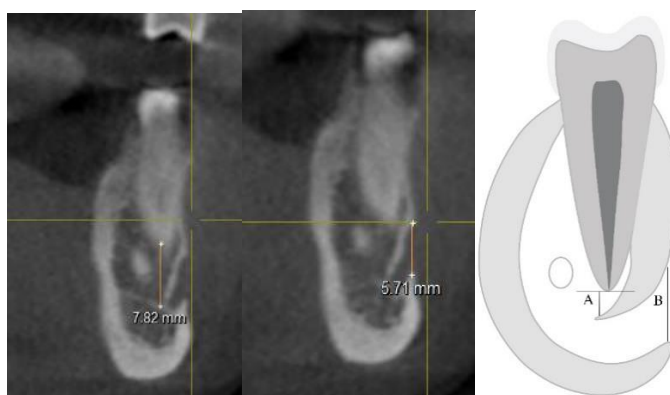


Fig. 1: Parameters: (A) Shortest distance of the foramen to adjacent tooth. (B) Height of the foramen



Fig. 2: (C) Angulation of mental canal in the coronal view. (D) Angulation of mental canal in the axial view. (E) Width of the foramen

Descriptive and inferential analysis was performed using SPSS Statistics 21.0 (SPSS Inc. Chicago, IL) for Windows. A critical value of $P < 0.05$ were considered statistically significant. Ethical approval was obtained from the Ethical Committee of the College of Dental Medicine in the University of Sharjah.

Results

A sample of 66 MF was evaluated during the period of the study (from November 2014 to April 2015). Statistical analysis on the significance of variation between the right and left side of the face did not show any statistical significance, thus the right and left side parameters were added together.

The mean height of the Mental Foramen was 3.77 mm \pm 0.86 mm in males and 3.10 mm \pm 0.8mm in females.

Table 1: Analysis of parameters in 66 subjects divided by gender

	Patient gender	N	Mean	Std. Deviation	Significance	T-test
Height of foramen	Male	28	3.7693	.86451	0.002	3.158
	Female	38	3.0950	.84764		
Width of foramen	Male	28	4.0068	1.16531	0.328	1.111
	Female	38	3.7138	.89510		
Shortest distance of foramen to adjacent tooth	Male	28	4.6783	3.22791	0.012	-.042
	Female	38	4.7071	1.94289		
Angulation in the coronal view	Male	28	37.8107	12.60527	0.545	-.150
	Female	38	38.3184	14.89727		
Distance from foramen to lower border of the mandible	Male	28	14.4382	1.84436	0.328	.973
	Female	38	14.0271	1.47039		
Angulation in axial view	Male	28	52.1500	22.35545	0.52	-.258
	Female	38	53.4397	16.38956		

There was a statistical significance between the mean value for the height of the foramen between males and females(P value = 0.002).

Regarding the width of the foramen, males had a mean value of 4.00 mm±1.16 mm while females had a mean value of 3.71 mm±0.89 mm with non-significant gender differences.(P value = 0.328).

The shortest distance of the foramen to the adjacent tooth was also measured, it showed statistically significant differences between male and female groups, (p=m0.012).

Males displayed a mean distance from either the first of second premolar depending on which had closer proximity to the mental foramen of 4.68mm±3.23mm while females had a mean distance of 4.71 mm±1.94 mm. Males showing mental foramina more closely related to the roots of adjacent teeth.

The distance from the center of the mental foramen to the lower border of the mandible showed no statistically significant gender -differences(P value = 0.328) with mean measurements of 14.4 mm±1.84mm and 14.02mm±1.84 mm respectively.

Furthermore, measurements on the Mental Foramen angulation in the coronal view had a mean value of 37.81⁰±12.60⁰ for males and 38.31⁰±14.90⁰ for females without reaching statistical significant differences. Finally, the angulation of the mental foramen when viewed in the axial plane was with a mean value of 52.15⁰ for males and 53.43⁰±16.39⁰ in females with a P value = 0.052.

Discussion

The present study demonstrated a significant difference - in the proximity of the mental foramen to the adjacent tooth and in the height of the mental foramen between males and females which was about 0.67 mm. greater in males. The discrepancy between males and females when it comes to the height of the

foramen can be related to the generally larger built of the males than females. This observation is in agreement with previous studies done by Souaga et al,⁽⁹⁾ who showed the same difference in the height of the foramen.

Similar findings were also made by Ayad et al⁽¹⁰⁾ and Göregen et al⁽²⁾ who showed greater height of the MF in males than females. The mean height of the UAE sample measured was 3.77 mm for males and 3.1 mm for females. MF was measured in sample from Turkish population by Göregen et al⁽²⁾ whose results were 3.6 mm for males and 3.3 mm for females. The differences were much less than that of the present study (0.3 versus 0.67mm). However, when the MF height is compared to the study done on a sample of an Ivory Coast population, the Emirati population showed a lower height when compared with ivory coast population (5.66 mm versus4.99 mm) for males and females respectively.

The width of the MF revealed a non-significant difference between males and females in the present study, this was in accordance with other studies^(9,10,12) who evaluated the MF of Ivorian, Sudanese and Turkish populations respectively. Other studies conducted by Sivavadivel et al⁽¹¹⁾ and Vonxarx et al⁽¹²⁾ showed a similar mean width of MF in both male and females of 3.4mm. Another study conducted on a Thai population by⁽¹³⁾ showed a smaller mean width of the foramen when compared to that of the Emirati population, this could possibly be attributed to the smaller body built of Thi peoples or their smaller skull size.

In the present investigation, the distance to the lower border of the mandible showed non-significant gender difference which is consistent with the findings of Souga et al⁽⁹⁾ and Von arx et al.⁽¹²⁾ This previously mentioned studies showed a constant central position of the MF in the frontal plane. Yet the results of

Sivavadivel et al,⁽¹¹⁾ performed on an Indian population showed a distance of 12.7 mm. The discrepancy could be due to different method used in t measurement. Beside the ethnic differences that are directly affect the results.

The shortest distance of MF to the adjacent tooth was measured according to the tooth closest to the foramen. The significant difference between males and females could result from the proximity of the foramen to different teeth. Von Arx et al⁽¹²⁾ showed that the mean distance of the foramen to the adjacent tooth was 4.4 mm in males and females. The present study however showed a wide variation of the mean values(4.68±3.23 mm). Von Arx et al⁽¹²⁾ first recorded angulation in the coronal and axial view. Angulation in the coronal view was close of statistical difference between males and females of the Emirati population, which means that the orifice of the MF opens in the same direction and can also be linked to the MF having similar width in males and females. Angulation in the coronal view was measured in the same way mentioned by Von Arx et al⁽¹²⁾ however the mean value obtained was different, this could either be due to inaccuracy in the method of obtaining the measurement or due to the presence of a difference in the angulation in a coronal view, even though no significant difference is evident between male and female samples in the present study. The mean angle of MF to ----- were of $38.31^{\circ} \pm 14.90^{\circ}$ and $37.81^{\circ} \pm 12.60^{\circ}$ in females and males. These values were smaller than that vari-obtained by Von Arxetal.⁽¹²⁾

Conclusions

The mental foramen is an important anatomical landmark in dentistry when giving local anesthesia or performing surgery in its close vicinity. However, some consideration needs to be given to the height of the foramen and its distance to the most adjacent tooth when dealing with male and female patients in the United Arab Emirates. Differences in the height of the foramen when dealing with different ethnicities should be considered. This study is preliminary study, further studies could be undertaken on a larger scale to derive more accurate results regarding the identification of the specific location of the MF in relation to the adjacent teeth.

Clinical Significances

MF location should be identified while keeping in mind the possibility of an anterior loop of the mental nerve being present mesial to the mental foramen. This should also be noted whilst performing surgery for implant placement.

Acknowledgment

The authors would like to thank Dr. Saad Wahbi Al Bayatti, Oral & Craniofacial Health Sciences Department, College of Dental Medicine for his assistance and support. The authors deny any conflicts of interest related to this study.

References

1. Singh R, Srivastava A. K. Study of Position, Shape, Size and Incidence of Mental Foramen and Accessory Mental Foramen in Indian Adult Human Skulls. *Int. J. Morphol.*, 2010;28(4):1141-1146.
2. Göregen M, Miloğlu Ö, Ersoyl, Bayrakdar I, Akgül H. The assessment of accessory mental foramina using cone-beam computed tomography. *Turk J Med Sci*, 2013;43:479-483.
3. Alamri HM, Sadrameli M, Alshalhoob MA, Sadrameli M, Alshehri MA. Applications of CBCT in dental practice: a review of the literature. *Gen Dent* 2012;60(5):390-400.
4. Verma M, Soni S, Saxena A, Das AR. Unilateral variation of the mental foramen. *OA Case Reports* 2013;10;2(11):102.
5. C. Stavrianos, A. Eliades, I. Stavrianou. Paresthesia of the Mental Nerve Due to Chronic Apical Periodontitis of a Non-Vital Tooth: A Case Report. 2010;4(2):94-97.
6. Moiseiwitsch J, Position of the mental foramen in a North American, white population, *OOOE*. 1998;85(4):457-460.
7. Greenstein G, Tarnow D, The Mental Foramen and Nerve: Clinical and Anatomical Factors Related to Dental Implant Placement, *Journal of Periodontology*. 2006;70(12): 1933-1943.
8. Renton T, Yilmaz Z.J, Profiling of patients presenting with post traumatic neuropathy of the trigeminal nerve, *Orfac Pain*. 2011; 25(4):333-44.
9. Souaga K, Adou A, Angoh Y. Topographical and morphological study of the mandibular foramen in black Africans from the Ivory Coast. *Odontostomatol Trop* 2004 Mar;27(105):17-21.
10. Ayad C, Gar-el-nabi M, Alhag A, M.E Tagreed, M.A Fatin, K Ismaeel, Alsafi, et al. Anatomical variations of mental foramen in Sudanese populations. *AJMCS* 2013;2:155-158.
11. Sivavadivel, S, Navaneetha, C, Kumar. An Anthropometric analysis of Mental Foramen in South Indian Population: A Dry Mandible Study. *jmpr*. 2015;3(3).
12. Von Arx T, Friedli M, Sendi P, Lozanoff S, Bornstein MM. Location and dimensions of the mental foramen: a radiographic analysis by using cone-beam computed tomography. *J Endod* 2013;39(12):1522-1528.
13. Apinhasmit W, Chompoopong S, Methathathip D, Sansuk R, Phetphunphiphat W. Supraorbital Notch/Foramen, Infraorbital Foramen and Mental Foramen in Thais: anthropometric measurements and surgical relevance. *J Med Assoc Thai*, 2006;89(5):675-682.