

Exophytic reactive lesions of the gingiva – “hard fibroma” a case report type of article: case report

Anita S. Raikar^{1,*}, Sanjeevini A. Hattarki²

¹PG Student, ²Senior Lecturer, Dept. of Periodontology, Maratha Mandal's Nathaji Rao Halgekar Institute of Dental Sciences, Belgaum

***Corresponding Author:**

Email: anita.raikar21@gmail.com

Abstract

Exophytic gingival lesions represent some of the more frequently encountered lesions in the oral cavity. Some of the most commonly encountered exophytic gingival lesions are the irritation fibroma, peripheral ossifying fibroma, pyogenic granuloma, and peripheral giant cell granuloma.^[1] Data from several biopsy services have indicated that 77% of lesions are reactive in nature.^[2] These lesions are a result of trauma or chronic irritation, or they can arise from cells of the periodontium, periodontal ligament, or periosteum. The case demonstrates the need for awareness, and the role of biopsy and histologic evaluation in the management of these lesions.

Keywords: Benign Gingival Tumor, Irritation Fibroma, Hard fibroma

Introduction

The fibroma is the most common oral fibrous growth, others being peripheral ossifying fibroma, pyogenic granuloma, and peripheral giant cell granuloma.¹ The occurrence rate of fibromas is 1%-5% in 1,453 lesions detected in more than 23,000 individuals over 35 years of age. The irritation fibroma was found at a prevalence rate of 12.0 lesions/1,000 people.² Most fibromas represent focal fibrous hyperplasia due to trauma or local irritation³. The duration of the lesion is often weeks to months due to the slow growth and mild symptoms; they are rarely painful, but often interfere with adequate plaque control. Since their duration is long, it is not uncommon to see ulceration to the epithelial surface from trauma. They are slow growing spherical tumor that tends to be firm & nodular but may be soft and vascular. Traumatic fibroma is a dome-shaped soft tissue mass usually found on buccal mucosa along the line of occlusion. Less frequently they may be found on lips and tongue. They are among the most common oral soft tissue lesions. Here we present a case report of hard gingival fibroma, diagnosed clinically and confirmed based on routine histopathological examination of an excised gingival enlargement⁴⁻⁷ with the identification of increased cellular content of fibroblast in the connective tissue.

Case Report

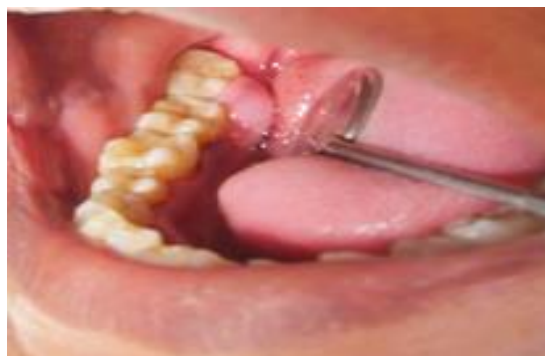

Fig. 1

A healthy, 58-year-old, female, was referred to Department of periodontology for periodontal treatment, exhibited a gingival mass that measured 5 x 5 mm (**Fig. 1**). This sessile rather pedunculated lesion had a smooth surface, firm and hard in consistency and was located lingually between 2nd and 3rd molar in the fourth quadrant. She stated it had been there for 6 months and according to the patient it had grown in size during the past 3 weeks. A periapical radiograph displayed no radiolucency between the apices of teeth 47 & 48 (**Fig. 2**). Both the teeth in the quadrant were tested vital, but distal caries was found reaching the distal pulp horn with 46.

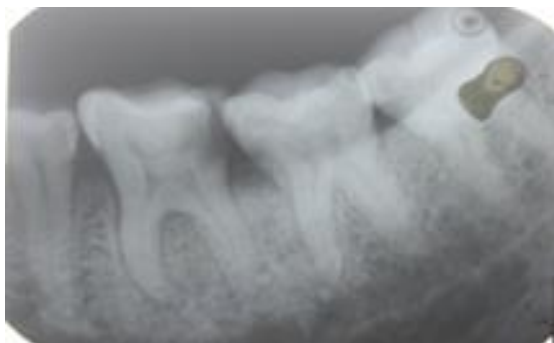


Fig. 2

A provisional diagnosis of fibroma was made based on the clinical features of the lesion.

Differential diagnosis included the following lesions: peripheral giant cell granuloma, pyogenic granuloma, giant cell fibroma and peripheral ossifying fibroma.

Treatment of lesion

After clinical and radiographic diagnosis, a complete treatment was planned to get the best possible results. Non-surgical periodontal therapy was performed that included scaling, root planing and polishing followed by oral hygiene instructions given to the patient. The surgical site was approached from the lingual side where an excisional biopsy was performed, and then the root surfaces were also debrided using a curette. After excision of the tissue the surgical site was covered using a periodontal dressing. The excised tissue was then placed in 4% neutral buffered formalin and sent for histopathological examination. Patient was recalled on the 7th day after surgery and the surgical site was checked where in the site showed satisfactory healing.

Histopathological examination

On histopathology examination, it showed normal to parakeratinized stratified squamous epithelium. The underlying connective tissue showed thick, long wavy collagen fibers arranged with spindle shaped and stellate shaped fibroblasts.

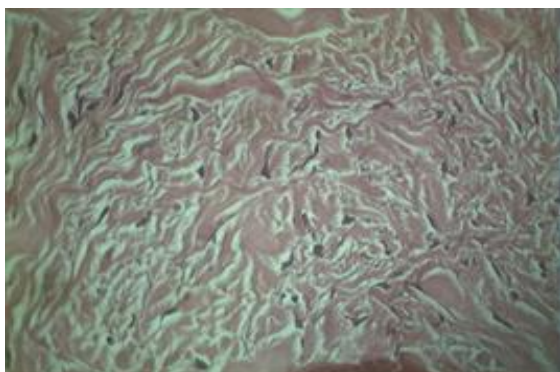


Fig. 3

H & E 40 x thick wavy collagen bundle arranged haphazardly with spindle and stellate shaped fibroblasts

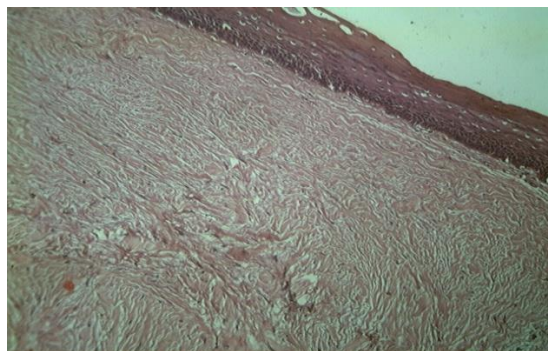


Fig. 4

H & E 10 x Parakeratinized Stratified Squamous Epithelium Overlined By Thick Dense Bundles of Collagen Arranged Parallel To Overlying Epithelium

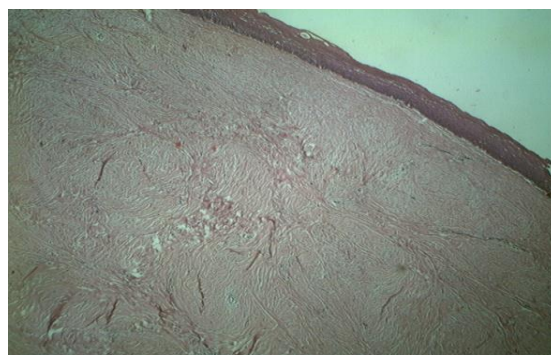


Fig. 5

H & E 4x Overlying Epithelium Is Atrophic

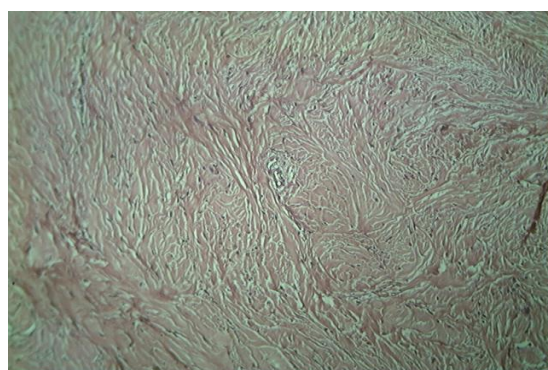


Fig.6

Hyperplastic stratified squamous epithelium with elongated rete ridges.

Discussion

Increase in size is a common feature of gingival disease. Current terminology accepted for this condition is gingival enlargement and gingival overgrowth. Zackheim HS et al conducted a survey of 257 oral tumors

in which approximately 8% occurred in gingiva.⁸ Many names have been given to similar lesions, such as, epulis, peripheral fibromas with calcification, peripheral ossifying fibromas, calcifying fibroblastic granuloma, peripheral cementifying fibroma, peripheral fibroma with cementogenesis, and peripheral cemento-ossifying fibroma.¹⁰⁻¹¹

Most fibromas represent focal fibrous hyperplasia due to trauma or local irritation. This lesion generally presents as a painless, sessile or occasionally pedunculated, round or ovoid, broad-based swelling that is lighter in color than surrounding tissue due to a reduced vascularity. Fibroma of the gingiva arises from the gingival connective tissue or from the periodontal ligament. They are slow-growing, spherical tumors that tend to be firm and nodular, but may be soft and vascular. The terms hard and soft fibroma are used to describe such lesions.

Hard fibromas of the gingiva are rare; most of the lesions diagnosed clinically as “fibromas” are inflammatory enlargements.⁹ Gingival fibroma affects people of all ages and both genders, but has a high frequency in female adults. The essential etiological factors are trauma and chronic irritation, particularly from the subgingival plaque and calculus. Eversole and Rovin¹³ stated that the constant irritation present during exfoliation of the deciduous teeth and eruption of the permanent teeth may also result in an increased incidence of reactive lesions, which originate from the periodontal ligament. This hypothesis is based on the fact that hard fibroma arise exclusively on the gingiva.

However, according to previous reports, there is correlation between the consistency and the histologic appearance of the lesion in the present case¹³. In the present case, there was no evidence of mineralization, e.g. bone, osteoid, acellular cementum, or dystrophic calcification. Hence, a histopathological diagnosis of gingival fibroma was given owing to the presence of abundant fibroblasts and dense bundles of collagen fibres. However, they usually respond to conservative surgical curettage or excision. Though occasionally seen in the oral cavity compared to the other reactive lesions, additional epidemiological studies are needed in order to more fully describe their characteristics.

Conclusion

This case report illustrate that exophytic gingival lesions are commonly encountered by dental clinicians. An important rule to remember regarding exophytic, sessile, gingival lesions is the 4 Ps. The differential diagnosis should include peripheral fibroma, peripheral ossifying fibroma, peripheral giant cell granuloma, and pyogenic granuloma. Other gingival conditions, such as medication-influenced overgrowth, certain neoplasms, or a hemangioma, can clinically resemble the lesions described. However, the ability to formulate a differential diagnosis is contingent upon clinical appearance as well as location. Ultimately, the diagnosis

is confirmed by biopsy and histologic evaluation. A hard fibroma is a slowly progressing lesion, the growth of which is generally limited. Many cases will progress for long periods before patients seek treatment, because of the lack of symptoms associated with the lesion. Treatment consists of surgical excision, scaling of the adjacent teeth. Postoperative follow-up is necessary because of the growth potential of incompletely removed lesions and an 8-20% recurrence rate. Further studies are needed on the distribution of the lesion in different ethnic and geographical populations.

References

1. McGinnis JP Jr. Review of the clinical and histopathologic features of four exophytic gingival lesions: the pyogenic granuloma, irritation fibroma, peripheral giant cell granuloma, and peripheral ossifying fibroma. *J Okla Dent Assoc.* 1987;77:25-30.
2. Bouquot JE, Gundlach KK. Oral exophytic lesions in 23,616 white Americans over 35 years of age. *Oral Surg Oral Med Oral Pathol.* 1986;62:284-291.
3. Weir JC, Davenport WD, Skinner RL. A diagnostic and epidemiologic survey of 15,783 oral lesions. *J Am Dent Assoc.* 1987;115:439-442.
4. Passos M, Azevedo R, Janini ME, Maia LC Peripheral cemento-ossifying fibroma in a child: a case report. *J Clin Pediatr Dent* 2007;32:57-9.
5. Kumar SK, Ram S, Jorgensen MG, Shuler CF, Sedghizadeh PP Multicentric peripheral ossifying fibroma. *J Oral Sci* 2006;48:239-43.
6. Batsakis JG Non-odontogenic tumors: clinical evaluation and pathology. In: *Comprehensive management of head and neck tumors 1999* 2nd ed., Thawley SE, Panje WR, Batsakis JG, Lindberg RD eds, W. B. Saunders, Philadelphia 1641-2.
7. Moon WJ, Choi SY, Chung EC, Kwon KH, Chae SW Peripheral ossifying fibroma in the oral cavity: CT and MR findings. *Dentomaxillofac Radiol* 2007;36:180-82.
8. Zackheim HS, Pinkus H. Perifollicular Fibromas. *Arch Dermatol* 1960;82:913-7.
9. Shah M et al. Peripheral giant cell fibroma: A rare type of gingival overgrowth. *J Indian Soc of Periodontol* 2012;16:2.
10. Bhaskar SN, Jacoway JR. Peripheral fibroma and peripheral fibroma with calcification: Report of 376 cases. *J Am Dent Assoc* 1966;73:1312-20.
11. Gardner DG. The peripheral odontogenic fibroma: An attempt at clarification. *Oral Surg Oral Med Oral Pathol* 1982;54:40-8.
12. Eversole LR, Sabers WR, Rovein S. Fibromy dysplasia: A nosology problem in the diagnosis of fibro-osseous lesion of the jaw. *J Oral Pathol* 1972;1:189-220.
13. Shafer, William G: A textbook of oral pathology 4th edition: pg 139.