

The Relationship between Radiographic Changes in Digital Panoramic Image and Osteoporosis in Post-Menopausal Women

Nemat Hmesh^{1,*}, Samira Zraiki²

¹PG Student, ²HOD, Dept. of Oral Medicine, Faculty of Dentistry, Tishreen University, Syria

***Corresponding Author:**

Email: dr_namat@hotmail.com

Abstract

Objectives: To evaluate the correlation between radiographic signs of structural bone changes in digital panoramic image and the bone mineral density (BMD) assessed by dual X-ray absorptiometry (DXA) and to assess the utility of panoramic radiographs in early detection of post-menopausal osteoporosis.

Methods: Fifty post-menopausal women between the ages of 43 years and 68 years were evaluated. Cortical width, cortical index, panoramic mandibular index, temporomandibular joint (TMJ) condylar morphology changes and the number of missing teeth were measured and evaluated from digital panoramic radiographs (DPR). Weight, height, menopausal status, age and temporomandibular disorders of the patients were recorded by questionnaire. BMD of the patients were measured with dual energy X-ray absorptiometry of Lumbar spine vertebrae (L1-L4) and left femoral neck for each participant.

Results: Pearson correlation coefficient test revealed that CW, PMI and NMT correlated with vertebral BMD and there were significant differences between groups with a statistically significant p-value < 0.05. Pearson Chi-Square test showed that CI correlated with BMD but TMJ condylar morphology changes didn't.

Conclusion: TMJ condylar morphology changes and TMD weren't correlated and couldn't predict low BMD, whereas CW, PMI and NMT were indicators for osteoporosis but not osteopenia in post-menopausal women and dental panoramic radiographs serve as a useful screening tool for early diagnosis of osteoporotic fractures.

Keywords: Osteoporosis, Digital Panoramic Radiography, Menopause, Temporomandibular Joint.

Introduction

Osteoporosis is a condition characterized by a loss in bone mineral density and micro-architectural deterioration in bone tissue leading to fractures.^{1,2} Bone fractures are the most serious complication of osteoporosis, with fractures most commonly affecting the vertebrae, femur and forearm.³ In Syria, It is estimated that there are about 15,000 vertebral fractures each year of which only 20% are treated by a doctor.⁴ It is estimated that over 200 million people worldwide suffer from this disease.⁵ Most of the cases are in women (90%), with Caucasian and Asian women at the highest risk.^{6,7} Post-menopausal women constitute more than 15% of the population in developed countries whereas this rate is 5–8% in less developed regions of the world.⁸ By 2030, the world population of menopausal and post-menopausal women is expected to increase to 1.2 billion, with 47 million new cases each year.^{8,9} Osteoporosis and fractures are more difficult and costly to treat than to prevent.

Therefore, a considerable effort has been made to identify methods of detecting individuals with osteoporosis at an early stage, as the institution of preventive therapy can limit the disease process. A DXA (dual-energy X-ray absorptiometry) scan, which is used to measure spine and hip bone density, is the most common technique for assessing the risk of osteoporosis.¹⁰ However, BMD testing for all postmenopausal women is not practicable in many third world countries where bone assessment methods, especially DXA, are not widely available.¹¹ Moreover,

the dentist is often the most regularly visited doctor in the elderly population, and use radiographs in everyday practice, so it is necessary to evaluate the possibility of recognizing decreased bone mineral density (BMD) on panoramic radiographs, particularly in menopausal and post-menopausal females.^{12,13} Other potential benefits of dental panoramic radiographs in comparison to the current gold standard techniques of diagnosing osteoporosis are: easy availability, cost effectiveness and safety resulting from minimal radiation exposure, etc.¹³ The authors suggested that the body of the mandible may be the most appropriate site for any planned assessment of the validity of mandibular measurements as a predictor of general bone mass.¹⁴ A lot of radiomorphometric indices of the mandible have been developed over the years by various authors to establish the correlation between altered mandibular morphological characters and osteoporosis,¹⁵ for example, cortical width,¹⁶ panoramic mandibular index,¹⁷ cortical index,¹⁸ radiographic changes of temporomandibular joint, and the number of lost teeth.¹⁹ Some of the investigators reported that they could be used in screening osteoporosis,^{16,17,18,19} but others reported that there was no relation between these parameters and osteoporosis.^{20,21}

The aim of the present study is the early diagnosis of osteoporosis by investigating the radiographic mandibular indices in digital panoramic image in a sample of post-menopausal women.

Materials and Methods

The sample consisted of 50 post-menopausal females aged between 43 years and 68 years (mean 52.7 ± 5.8 years) who visited the Radiography Department of OB\GYN & CHILDREN Hospital and Department of Oral Medicine, Faculty of Dentistry, Tishreen University with no previous osteoporosis diagnosis. All participants were in natural menopause (did not have menstruation for at least the last year) and none had known systemic disease that would affect bone metabolism (hyperparathyroidism, hypoparathyroidism, Paget's disease, osteomalacia, renal osteodystrophy, osteogenesis imperfect or rheumatoid arthritis), cancers with bone metastasis or significant renal impairment. They were not using specific drugs or hormones (corticosteroids, excess thyroid hormone) which are known to have adverse effects on bone metabolism, did not take protective (e.g. calcium or vitamin D) or replacement (e.g. bisphosphonates) therapy for osteoporosis and did not have thoracic fractures. They were non-smokers and did not drink alcohol.

Written informed consent was obtained from all of the study participants, and the performance of this study was approved by the board of the Dentistry School, Tishreen University.

The data regarding menopausal status, age, weight and height, were obtained by questionnaire. Another questionnaire used as a primary screening tool for temporomandibular disorders (90.3%- 97.7% sensitivity and 95.7%-100% specificity).²² It consists of eight questions relating to jaw pain (i.e. location of pain, precipitating factors, and temporal pattern of pain) and five questions relating to jaw function (i.e. joint noises, locking, and difficulty in opening). There were five possible answers to each question which ranged from 0 (no symptoms) to 4 (unbearable or constant symptoms). The total scores ≥ 6 considered positive tests (i.e., subjects are assumed to have TMD), and total questionnaire scores < 6 are considered negative tests (i.e., subjects are assumed not to have TMD).

Radiological examinations

The body bone densitometry tests for all participants were performed using dual X-ray absorptiometry (DXA) (Osteocore 3, Medilink) covering the lumbar spine (L1–L4). The participants were classified as normal ($T\text{-score} \geq -1$), osteopenia ($-1 > T\text{-score} > -2.5$) and osteoporosis ($T\text{-score} \leq -2.5$) according to the WHO classification.

Digital panoramic radiographs (DPR) were taken by KODAK 9000C Digital Panoramic and Cephalometric System (Carestream Health, Inc, Rochester, NY) at 140 kHz, 60–90 kV and 2–15 mA. The linear measurements and qualitative evaluations of the radiographs were performed using Kodak Dental Imaging Software (Kodak Dental Systems, Rochester, NY) for Windows 7. The images had a ratio of 1:1, and there was no need for magnification correction. The researcher performed the

entire measurement on the right and left side of the mandible when the mental foramen was visible bilaterally and their mean was used in the analysis; when only one foramen was visible, the measurements were done only on that side. Two weeks later the same researcher repeated the measurements and evaluation.

Morphometric measurements

50 DPR were analyzed for CW, PMI, CI, TMJ condylar morphology changes and the number of missing teeth. The information on age and BMD status of the patients was blinded to the researcher in order to eliminate information bias. According to Ledgerton et al two linear measurements were made using the following technique (Fig. 1):

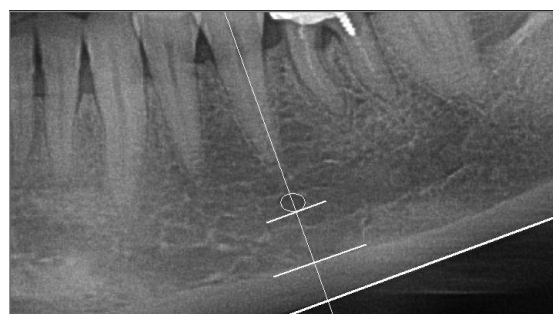


Fig. 1: Measurements on DPR: CW; PMI

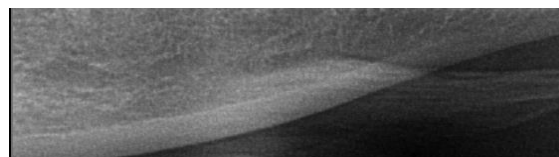
1 the mental foramen was identified;

2 a line was drawn which passed perpendicular to the tangent to the lower border of the mandible and through the center of the mental foramen;²³

3 measurements were made along this line of

- Cortical width (CW): the thickness of the cortical bone of lower border of mandible;
- The distance between the lower border of the mandible and the inferior margin of the mental foramen (inferior foramina distance, I);

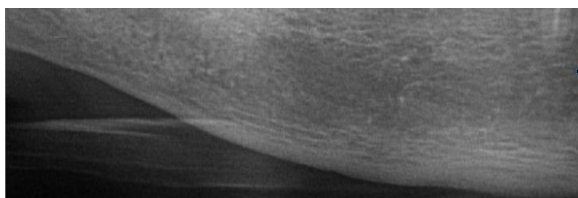
To evaluate the CI of the mandible, the morphology of mandibular inferior cortex was visually examined distally from the mental foramen bilaterally using Klemetti's classification (Fig. 2).



CI1



CI2



CI3

Fig. 2: Classification of mandibular cortical index CI

- CI 1: The endosteal margin of the inferior cortex is smooth on both ends.
- CI 2: The endosteal margin shows semilunar defects or appears to form endosteal cortical residues.
- CI 3: The cortex is obviously porous with dense endosteal residues.²⁴

TMJ condylar morphology changes as erosion in the radiographs was scored according to Helenius et al as follows:

Score 1 – very slight erosion; score 2 – erosion at the top of the condyle; score 3 – half of the condyle is eroded; score 4 – condyle totally eroded.²⁵ (Fig. 3)

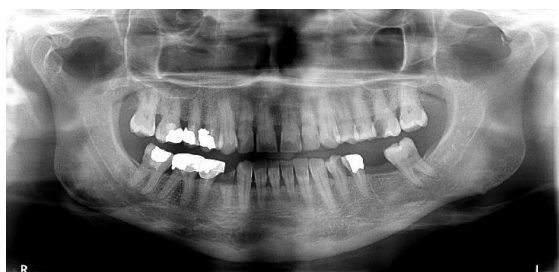

Fig. 3: DPR, Erosions of the left mandibular condyle were visible & irregularity of superior condylar surface was observed

The number of mandibular missing teeth, excluding third molars was recorded from panoramic radiographs. Root remnants were counted as teeth. The time and cause of tooth loss were unknown.

Statistical Analysis

ANOVA test with Fisher's Least Significant Difference (LSD) was used to determine whether there was a statistical significant difference between groups means in the parameters measured; CW, PMI, NMT and Pearson's Correlation Coefficient (r) was calculated to assess the direction and strength of the relationship between vertebral BMD and CW, PMI, NMT.

Determining the association between the groups and morphological changes in the mandibular cortex (CI), TMJ condylar and TMD was made by using chi-squared test. Logistic regression was used to measure the validity of TMJ and TMD in the diagnosis of reduced BMD and osteoporosis.

To assess the cut-off threshold values, receiver operating characteristic (ROC) curves was plotted for the

CW and PMI with MedCalc software (low BMD (osteopenia and osteoporosis) versus Normal) to compare the sensitivity and specificity of measurements. Area under the ROC curve (AUC) was also calculated and we had identified the values as follows; fail (AUC = 0.5–0.6), poor (0.6–0.7), fair (0.7–0.8), good (0.8–0.9) and excellent tests (0.9–1). P-values less than 0.05 were considered statistically significant.

SPSS v 23.0 software package was used for data entry and analysis.

Results

15 (30%) participants had a normal BMD, 13 (26%) participants had osteopenia and 22 (44%) participants had vertebral osteoporosis. Six variables were evaluated in this study for their relation with osteoporosis. Three of the variables were continuous (CW, PMI and NMT) and three of them were categorical data (CI, TMJ and TMD).

Table 1: ANOVA test for differences between groups means

Variable	F	Sig.
CW	8.387	.001
PMI	6.226	.004
NMT	3.665	.033

CW, cortical width; PMI, panoramic mandibular index; NMT, number of missing teeth

Table 2: Pearson chi-squared for association between the groups and CI, TMJ & TMD

		Value	df	Asymp. Sig. (2-sided)
CI	Pearson Chi-Square	15.834	4	.003
TMJ	Pearson Chi-Square	2.006	4	.735
TMD	Pearson Chi-Square	1.396	2	.498

CI, cortical index; TMJ, radiographic changes of temporomandibular joint condylar; TMD, temporomandibular joint disorders

ANOVA test and Fisher's LSD were used in comparing the differences of; CW, PMI, NMT for each BMD category (normal, osteopenia, osteoporosis). They showed that there are significant differences between mean of these variables in normal group and both the other two; osteopenia and osteoporosis (Table 1). None of the parameters evaluated were found to differ significantly between the osteopenia and osteoporosis group (p value > 0.005). Chi- squared test showed a significant association between CI and vertebral BMD (p= 0.003) but no association between TMJ and vertebral BMD (p= 0.735) or TMD and vertebral BMD (p= 0.498) (Table 2). In logistic regression analysis; TMJ and TMD were the Constants and osteoporosis was dependent

variable. Correlation coefficient was very weak found not to be predictors for osteoporosis (Table 3). (r=0.171). TMJ (p= 0.667) and TMD (p=0.319) were

Table 3: Logistic regression analysis

Model	Unstandardized Coefficients		Standardized Coefficients	t	Sig.
	B	Std. Error	Beta		
1 (Constant)	1.011	.176		5.730	.000
TMJ	.094	.217	.063	.432	.667
TMD	.279	.277	.148	1.008	.319

a. Dependent Variable: vertebral BMD

Pearson's correlation coefficient test demonstrated that CW, PMI positively correlated with BMD (r= 0.554, p= 0.0001) (r= 0.549, p= 0.0001) and NMT negatively correlated with BMD (r=0.33, p=0.019) (Table 4). ROC curve analysis showed that for mean CW AUC for identifying normal and low BMD (osteopenia and osteoporosis) groups was 0.818(95% confidence interval (CI), 0.683 to 0.913) with a statistically significant p-value <0.0001 (Fig. 4). For mean PMI AUC was 0.771(95% confidence interval (CI), 0.631 to 0.878) with a statistically significant p-value <0.0001(Fig. 5).

Table 4: Pearson correlation displaying direction & strength of the relationship

		NMT	CW	PMI	Vertebral BMD
NMT	Pearson Correlation	1	-.225-	-.183-	-.330-*
	Sig. (2-tailed)		.116	.204	.019
CW	Pearson Correlation	-.225-	1	.892**	.554**
	Sig. (2-tailed)	.116		.000	.000
PMI	Pearson Correlation	-.183-	.892**	1	.549**
	Sig. (2-tailed)	.204	.000		.000
Vertebral BMD	Pearson Correlation	-.330-*	.554**	.549**	1
	Sig. (2-tailed)	.019	.000	.000	

*. Correlation is significant at the 0.05 level (2-tailed).
 **. Correlation is significant at the 0.01 level (2-tailed).

The accuracy of AUC for identifying study groups by MCW was good accurate and by PMI was fair. In the present study, for identifying postmenopausal women with vertebral osteopenia and osteoporosis, MCW cutoff value was ≤ 2.9 mm with a low sensitivity (54.3%) but a very high specificity (100%) and PMI cutoff value was ≤ 0.2539 mm with a low sensitivity (51.4%) but a very high specificity (100%).

Discussion

There are extremely limited numbers of DXA machines available in Middle East. In Morocco, there are only 0.6 DXA machines per 1 million people.²⁶ Because skeletal BMD changes may accompany the altered density of other bones such as alveolar bone,^{17,28,29} practitioners across the whole world

attempted to explore the utility of panoramic radiographs in detection osteoporosis. Some authors have reported the use of digital panoramic radiographs.^{30,31} The advantages of digital techniques over film techniques are lower radiation, faster communication of images, smaller storage space requirement, and lower contamination of the environment,^{32,33} changes in brightness, contrast and magnification to improve the repeatability and reproducibility of any study.³³ Therefore this study aimed to correlate the radiographic findings on digital panoramic radiographs with vertebral BMD assessed by dual x-ray absorptiometry (DXA) to predict the efficacy of the radiographic methods in diagnosing osteoporosis.

The results showed that there were a significant association between CI and vertebral BMD (p= 0.003)

and severely eroded cortex (CI3) associated with the osteopenia and osteoporosis groups. Amorim et al. failed to identify an association between a finding of cortical erosion and osteoporosis diagnosis in 39 women aged 48–70 years.³⁴

On the other hand, Halling et al. considered elderly people with a severely eroded cortex detected on DPRs as having increased risk of reduced BMD (T score ≤ -1.5).³⁵

Furthermore, postmenopausal women with any degree of cortical erosion were at high risk of having osteoporotic spine fractures.³⁶

Panoramic radiograph has a common presentation: degenerative, when erosion and loss of the condylar outline are apparent, but there must be approximately 40% decalcification before bony erosions can be visualized. Furthermore, radiographic changes appear to develop some months after the clinical symptoms.³⁷

In this study, erosions of TMJ condylar were observed in 50% of participants, and only 28% of them had TMD. There were no association between TMJ and vertebral BMD ($p = 0.735$) or TMD and vertebral BMD ($p = 0.498$). Logistic regression analysis measured the validity of TMJ condylar erosions and TMD in diagnosing osteopenia and osteoporosis, showed that correlation coefficient was very weak ($r = 0.171$) and they considered not to be predictors for osteoporosis.

On the other hand, a population based study indicates that TMJ radiographic changes and teeth loss seems to be related to the low level of BMD.³⁸

Several studies have indicated that reduced skeletal BMD is associated with premature tooth loss.^{39,40,41,42} Such patterns of tooth loss may be correlated with periodontal attachment loss/disease and osteoporotic status.^{40,42,43,44} In this study; a significant negative correlation was found between: vertebral BMD and number of missing teeth (Pearson correlation coefficient -0.330 ; $p = 0.019$), and there was a significant difference in the mean of NMT between normal and osteoporosis group ($p = 0.011$) but no differences between normal and osteopenia group ($p = 0.073$) and between osteopenia and osteoporosis groups ($p = 0.579$).

There have, however, been studies that fail to show correlations between osteoporotic status and tooth number.^{45,46,47}

In a larger multi-center study of early post-menopausal women, Earnshaw found no association with BMD and tooth loss.⁴⁸

CW (cortical width) is the measurement of the thickness of the cortical bone of lower border of mandible in the region of mental foramen¹⁶, while PMI (panoramic mandibular index) is a quantitative radiomorphometric index of mandibular cortical bone mass and was calculated as the ratio of mandibular cortical thickness divided by the distance between the Inferior margin of mental foramen to the inferior border of the mandible.¹⁷

The present study compares CW and PMI of

postmenopausal women with vertebral BMD. It was observed that for normal group Mean CW was (3.75, SD= 0.45), however there was a decrease in the mean CW in osteopenia group (2.96, SD= 0.76) and osteoporosis (2.60, SD= 1.06) suggesting that MCW at the mental foramen region is thinner in the postmenopausal women with low vertebral BMD and was efficacious in differentiating patients affected by osteoporosis. However, differentiating osteopenia patients from those who have osteoporosis was not possible with these measurements. Results showed levels of significance to compare osteopenia group with osteoporosis were above $p = 0.05$ (CW, $p = 0.228$) (PMI, $p = 0.318$).

Devlin et al reported in their study named “The Osteodent Project” that the cortical index and cortical width are indicators of osteoporosis. The authors also concluded that when evaluating panoramic radiographs, only those patients with the thinnest mandibular cortices (i.e. < 3 mm) should be referred for further osteoporosis investigation Their study included six hundred seventy one post-menopausal women, aged 45 to 70 years of age; who underwent DXA scans of the left hip and lumbar spine (L1 to L4) and dental panoramic.⁴⁹ Gulsahi et al have reported that people with Mental Index (CW at the mental foramen region) < 3 mm, Panoramic Mandibular Index (PMI) < 0.30 may be seen as high risk patients for osteoporosis.⁵⁰ Our results were consistent with these studies, the cut off threshold of the CW was ≤ 2.9 mm and PMI was ≤ 0.25 at the mental foramen region.

There were few limitations to this study; the small sample size (50 subjects), and it was hospital based study rather than general population study. Defining the mental foramen and making measurements specially the linear ones had a great dependency on the examiner brain, eye, skill and experience. That's why; making measurements from panoramic radiographs is associated with essential errors and examiner variability.

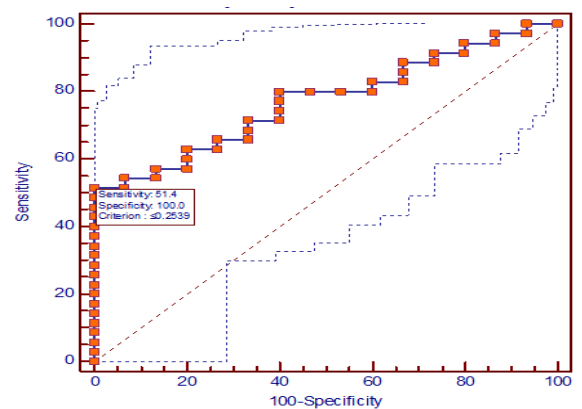


Fig. 4: Cortical width mean

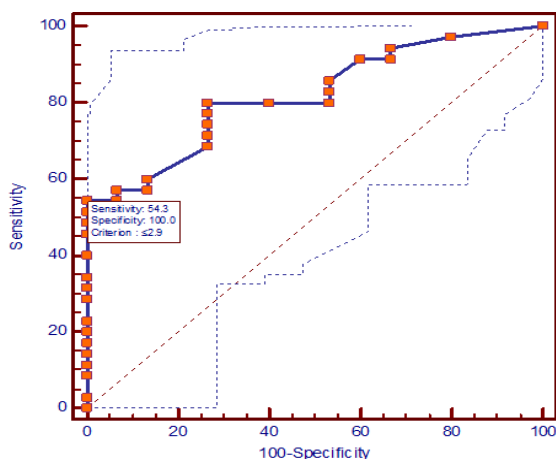


Fig. 5: Panoramic mandibular index mean

Conclusion

This study demonstrated that TMJ condylar morphology changes and TMD weren't correlated and couldn't predict low BMD, whereas the thickness and shape of the mandibular Cortex, panoramic mandibular index and number of missing teeth were indicators for osteoporosis but not osteopenia in post-menopausal women and the dentists community could use DPR as a screening tool for early diagnosis of osteoporosis and suggest further osteoporosis investigation.

References

1. Consensus Development Conference, Prophylaxis and treatment of osteoporosis. *Am J Med.* 1991 Jan;90(1):107-10.
2. Link TM, Majumdar S, Grampp S, Guglielmi G, van Kuijk C, Imhof H, et al. Imaging of trabecular bone structure in osteoporosis. *Eur Radiol.* 1999;9(9):1781-8.
3. Cvijeti'c S, Grazio S, Ka'stelan D, Kor'c M. Epidemiology of osteoporosis. [In Croatian] *Arh Hig Rada Toksikol* 2007;58:13-18.
4. The Middle East & Africa Regional Audit: Epidemiology, costs &burden of osteoporosis in 2011. International Osteoporosis Foundation. www.iofbonehealth.org/middle-east-africa-audit.
5. Kanis JA. WHO Technical Report, University of Sheffield, UK. 2007;66.
6. Riera-Espinoza G. Epidemiology of osteoporosis in Latin America 2008. *Salud Publica Mex.* 2009; 51 Suppl 1:S52-5.
7. Johnell O, Kanis J. Epidemiology of osteoporotic fractures. *Osteoporos Int.* 2005 Mar;16 Suppl 2:S3-7.
8. World Health Organization, Research on the menopause in the 1990s, report of A WHO Scientific Group. WHO technical report series 866. Geneva: World Health Organization; 1996.
9. Hill K. The demography of menopause. *Maturitas.* 1996 Mar;23(2):113-27.
10. World Health Organisation. Assessment of fracture risk and its implication to screening for postmenopausal osteoporosis: Technical report series 843. Geneva: WHO,1994.
11. Ishii K, Taguchi A, Nakamoto T, Ohtsuka T, Sutthiprapaporn P, Tsuda M, et al. Diagnostic efficacy of alveolar bone loss of the mandible for identifying postmenopausal women with femoral osteoporosis.

- Dentomaxillofac Radiol. 2007 Jan;36(1):28-33.
12. L'opez-L'opez J, Estrugo-Devesa A, Jane-Salas E, Ayuso-MonteroR, G'omez-Vaquero C. Early diagnosis of osteoporosis by means of orthopantomograms and oral x-rays: a systematic review. *Med Oral Patol Oral Cir Bucal.* 2011 Nov 1; 16(7):e905-13.
13. White SC. Oral radiographic predictors of osteoporosis. *Dentomaxillofac Radiol.* 2002 Mar;31(2):84-92.
14. Masud, T., Mootoosamy, I., Mc Closkey, EV, Sullivan, MPO, Whitby, ET. et al. Assessment of osteopenia from spine radiographs using two different methods: the Chingford Study. *Br J Radiol.* 1996 May;69(821):451-6.
15. Devlin, H. and Horner K. Mandibular radiomorphometric indices in the diagnosis of reduced skeletal bone mineral density. *Osteoporosis Int.* 2002 May;13(5):373-8.
16. Taguchi A, Tanimoto K, Suei Y, Otani K, Wada T. Tooth loss and mandibular osteopenia. *Oral Surg Oral Med Oral Pathol Oral Radiol Endod.* 1995 Jan;79(1):127-32.
17. Benson BW, Prihoda TJ, Glass BJ. Variations in adult cortical bone mass as measured by a panoramic mandibular index. *Oral Surg Oral Med Oral Pathol* 1991 Mar;71(3):349-56.
18. Klemetti E, Kolmakow S. Morphology of the mandibular cortex on panoramic radiographs as an indicator of bone quality. *Dentomaxillofac Radiol* 1997;26:22-25.
19. Jagur O, Kull M, Leibur E, Kallikorm R, Loorits D, Lember M, Voog-Oras U. Relationship between radiographic changes in the temporomandibular joint and bone mineral density. *Stomatologija* 2011;13(2):42-8.
20. Mohajery M, Brooks SL. Oral radiographs in the detection of early signs of osteoporosis. *Oral Surg Oral Med Oral Pathol.* 1992 Jan;73(1):112-7.
21. Drozdowska B, Pluskiewicz W, Tarnawska B. Panoramic based mandibular indices in relation to mandibular bone mineral density and skeletal status assessed by dual energy X-ray absorptiometry and quantitative ultrasound. *Dentomaxillofac Radiol.* 2002 Nov;31(6):361-7.
22. Geoffrey E. Gerstner, Glenn T. Clark, Jean- Paul Goulet. Validity of a brief questionnaire in screening asymptomatic subjects from subjects with tension- type headaches or temporomandibular disorders. *Community Dent Oral Epidemiol.* 1994;22:235-42.
23. Ledgerton, D., Horner, K., Devlin, H. and Worthington, H. Panoramic mandibular index as a radiomorphometric tool: an assessment of precision. *Dentomaxillofac Radiol.* 1997 Mar;26(2):95-100.
24. Klemetti, E., Kolmakov, S. and Kroger, H. Pantomography in assessment of the osteoporosis risk group. *Scand J Dent Res.* 1994 Feb;102(1):68-72.
25. Helenius L, Hallikainen D, Meurman J, Koskimies S, Tervahartiala P, Kivisaari L, et al. HLA-DRB1* alleles and temporomandibular joint erosion in patients with rheumatic disease. *Scand J Rheumatol.* 2004;33(1):24-9.
26. The Middle East & Africa Regional Audit: Epidemiology, costs &burden of osteoporosis in 2011. International Osteoporosis Foundation. www.iofbonehealth.org/middle-east-africa-audit.
27. Kribbs PJ, Chesnut CH 3rd, Ott SM, Kilcoyne RF. Relationships between mandibular and skeletal bone in a population of normal women. *J Prosthet Dent.* 1989 Dec;62(6):703-7.
28. Megan R. Fractures, Spine Osteoarthritis Inversely Linked With Osteoporosis. *Ann Rheum Dis* 2008;67:224-228.
29. Kral EA, Dauson -Hughes B, Papas AS, Carica RI. Skeletal bone density and bone loss. *J Dent Res* 1993;72:63.
30. Satish A, Reddy R, Ramesh T, Ramya K, Naveen B, Saikiran Ch. Identifying risk groups for osteoporosis by

- digital panoramic radiography. *Contemporary Clinical Dentistry* 2015;6:253-257.
31. I Savic Pavicin, J Dumancic, T Jukic, T Badel, A Badanjak. Digital orthopantomograms in osteoporosis detection: mandibular density and mandibular radiographic indices as skeletal BMD predictors. *Dentomaxillofac Radiol.* October 2014;43(7):20130366.
 32. Devlin H, Horner K. Diagnosis of osteoporosis in oral health care. *J Oral Rehabil.* 2008 Feb;35(2):152-7.
 33. Molander B, Gröndahl HG, Ekstubbbe A. Quality of film-based and digital panoramic radiography. *Dentomaxillofac Radiol.* 2004 Jan;33(1):32-6.
 34. Amorim MA, Takayama L, Jorgetti V, Pereira RM. Comparative study of axial and femoral bone mineral density and parameters of mandibular bone quality in patients receiving dental implants. *Osteoporos Int* 2006;17:1494–500.
 35. Halling A, Persson GR, Berglund J, Johansson O, Renvert S. Comparison between the Klemetti index and heel DXA BMD measurements in the diagnosis of reduced skeletal bone mineral density in the elderly. *Osteoporos Int.* 2005 Aug;16(8):999-1003.
 36. Taguchi A, Ohtsuka M, Nakamoto T, Naito K, Tsuda M, Kudo Y, et al. Identification of postmenopausal women at risk of osteoporosis by trained general dental practitioners using panoramic radiographs. *Dentomaxillofac Radiol.* 2007 Mar;36(3):149-54.
 37. Gray, Robin J. M., Al-Ani, M. Ziad. *Temporomandibular Disorders: A problem-based approach.* 1st edition. Wiley Blackwell; 2011.
 38. Jagur O, Kull M, Leibur E, Kallikorm R, Loooris D, Lember M, Voog-Oras U. Relationship between radiographic changes in the temporomandibular joint and bone mineral density: A population based study. *Stomatologija*, 2011;13(2):42-8.
 39. Nicopoulou-Karayianni K, Tzoutzoukos P, Mitsea A et al. Tooth loss and osteoporosis: the OSTEODENT study. *J Clin Periodontol.* 2009 Mar;36(3):190-7.
 40. Streckfus C F, Johnson R B, Nick T, Tsao A, Tucci M. Comparison of alveolar bone loss, alveolar bone density and second metacarpal bone density, salivary and gingival crevicular fluid interleukin-6 concentrations in healthy premenopausal and postmenopausal women on estrogen therapy. *J Gerontol A Biol Sci Med Sci.* 1997 Nov;52(6):M343-51.
 41. Daniell HW. Postmenopausal tooth loss. Contributions to edentulism by osteoporosis and cigarette smoking. *Arch Intern Med.* 1983 Sep;143(9):1678-82.
 42. Inagaki K, Kurosu Y, Kamiya T et al. Low metacarpal bone density, tooth loss, and periodontal disease in Japanese women. *J Dent Res* 2001;80:1818–1222.
 43. Von Wowern N, Klausen B, Kollerup G. Osteoporosis: a risk factor in periodontal disease. *J Periodontol.* 1994 Dec;65(12):1134-8.
 44. Offenbacher S. Periodontal diseases: pathogenesis. *Ann Periodontol.* 1996 Nov;1(1):821-78.
 45. May H, Reader R, Murphy S, Khaw K T. Self-reported tooth loss and bone mineral density in older men and women. *Age Ageing* 1995;24(3):217-221.
 46. Elders PJ, Habets LL, Netelenbos JC, van der Linden LW, van der Stelt PF. The relation between periodontitis and systemic bone mass in women between 46 and 55 years of age. *J Clin Periodontol.* 1992 Aug;19(7):492-6.
 47. Weyant R J, Pearlstein M E, Churak A P, Forrest K, Famili P, Cauley J A. The association between osteopenia and periodontal attachment loss in older women. *J Periodontol* 1999 Sep;70(9):982-9.
 48. Earnshaw S A, Keating N, Hosking D J et al. Tooth counts do not predict bone mineral density in early postmenopausal Caucasian women. EPIC study group. *Int J Epidemiol* 1998;27:479–483.
 49. Devlin, H., Karayianni, K., Mitsea, A., Jacobs, R., Lindh, C., Stelt, P.V. et al. Diagnosing osteoporosis by using dental panoramic radiographs: Osteodent Project. *Oral Surg Oral Med Oral Pathol Oral Radiol Endod.* 2007 Dec;104(6):821-8.
 50. Gulsahi, A., Yuzugullu, B., Imrzalioglu, P. and Genc, Y. Assessment of panoramic radiomorphometric indices in Turkish population of different age groups, gender and dental status. *Dentomaxillofac Radiol* 2008;37:288-92.