

## Occlusal Vertical Dimension and Amelogenesis imperfecta: Systematic Review of the Literature

Sinda Ammar<sup>1</sup>, Insaf Farhat<sup>2</sup>, Amel Labidi<sup>3,\*</sup>, Imed Ouni<sup>4</sup>, Sonia Ghoul-Mazgar<sup>5</sup>

<sup>1,2</sup>DDS, MCA, <sup>3,4</sup>DDS, Dental Resident, <sup>5</sup>DDS, PhD, Prosthodontic Department & Laboratory of Histology and Embryology, Faculty of Dental Medicine, University of Monastir, Avicenna Avenue, 5019 Monastir, Tunisia

**\*Corresponding Author:**

Email: amellabidi16@yahoo.fr

---

### Abstract

**Statement of problem:** Amelogenesis imperfecta (AI) is a genetic disorder that causes defective enamel development in both primary and permanent dentition. Significant tooth structure damage often results in occlusal disharmony affecting the patient's occlusal vertical dimension (OVD).

**Purpose:** The purpose of this study was to review the current data in OVD evaluation and its reestablishment during the treatment of amelogenesis imperfecta patients.

**Method and Materials:** Relevant publications on OVD evaluation in amelogenesis imperfecta patients were thoroughly reviewed from the literature published between the years 1994 and 2014: With no restrictions criteria on the language of publications or the types of articles. The search strategy was developed using a combination of controlled vocabulary and the final update was stopped on November 2014.

**Results:** The exploration of Medline identified, in this systematic review, 20 articles. Only 13 of them were selected after screening. All the studies were case reports describing 14 patients (7 males/ 7females, age: from 7 to 45 years old) with amelogenesis imperfecta treated with different approaches. While OVD was modified in 13cases, there was a lack of information concerning the OVD evaluation and treatment.

**Conclusion:** According to this study, it seems important to systematically explore OVD in all AI patients, to preferably evaluate it by cephalometric method and to reestablish it by a prosthetic approach.

---

### Introduction

The occlusal vertical dimension (OVD) is defined as the distance between two selected anatomic points when the mandibular teeth are occluding with the maxillary teeth.<sup>1</sup> This OVD, mainly determined by teeth, and could be affected by tooth wear. Fast acting wear could change OVD whereas slow acting wear is unlikely to affect it due to secondary extrusion. Patients with dental abnormalities are more prone to fast acting wear and thus OVD loss. Several methods have been described in the literature to evaluate OVD. These methods include either extraoral considerations such as the evaluation of interocclusal rest space, facial esthetics and temporomandibular joint status, or intraoral considerations such as the remaining tooth structures and occlusion.<sup>2</sup> However, the multiplicity of these techniques may indicate limited predictability and consistency. Otherwise, therapeutic modifications of OVD should be approached with caution as it has often been considered to interfere with the physiology of the masticatory system as well as esthetics.<sup>3</sup>

Considering amelogenesis impertecta (AI) as a kind of dental anomaly, it is important to notice that AI includes a group of hereditary disorders that affect the quality and/or the quantity of enamel in both primary and permanent dentition. Its prevalence vary between 1/700,<sup>4</sup>and 1/14000,<sup>5</sup> and according to the Witkop's classification, revised by Nusier et al.,<sup>6</sup> there are four main forms of AI: hypoplastic, hypocalcified, hypomatured, and AI with taurodontism. In fact, this disease is known for the structure anomalies of the

enamel, but it is also frequently associated with either to dental anomalies such as a reduction of the crown size, agenesis and extensive loss of tooth tissues or with skeletal anomalies and malocclusions such as open bite and cross bite.<sup>7,8</sup> These anomalies are thought to affect OVD and the treatment options should therefore consider this parameter in order to restore functions and esthetics.

The aim of this study was: to review current data into OVD evaluation and its reestablishment during the treatment of patients with Amelogenesis Imperfecta.

### Methods

The literature search for relevant articles was performed in MEDLINE database using PubMed.

The search strategy was developed using the terms "Vertical Dimension" [Mesh] and "Amelogenesis Imperfecta" [Mesh]. Since the literature on such broad subjects would be abundant, the review focused on selected combinations of the two search terms: "Vertical Dimension" [Mesh] AND "Amelogenesis Imperfecta" [Mesh]. The final update of the search was on November 2014. Publications considered to present the highest level of evidence, i.e. clinical randomized controlled trials (RCT) and systematic reviews were not available (Table 1).

The exclusion Criteria included the date of publication (<1994). There was no restriction criteria on the language of publications or on the type of articles. Only the findings described by the authors in these papers were used. Clinical photographs or radiographs

were not used to include additional findings. Data were extracted by five reviewers independently using pre-established checklist for data extraction. In case of disagreements, consensus was achieved by discussion among the reviewers.

## Results

- Articles selection:** After the search on PubMed, 20 articles were obtained. Considering the exclusion criteria, 13 articles were selected according to the diagram of article selection (Fig. 1). Seven papers were excluded, 3 articles because the date of publication (<1994),<sup>9,10,11</sup> and 4 articles after reading for several reasons as mentioned in Table 2.<sup>12,13,14,15</sup> Thirteen papers were selected after screening.<sup>16,17,18,19,20,21,22,23,24,25,26,27,28</sup> All the studies were case reports describing one patient except a paper describing two patients.<sup>28</sup>
- Patient's characteristics (Table 3):** Fourteen patients were described, seven males and seven females. Their age varied from 7 to 45 years old. Only four patients were in mixed dentition while 10 patients were in permanent dentition. Concerning the type of amelogenesis imperfecta, hypoplastic type was described in 7 cases, hypocalcified and hypomaturation type were found in two cases for each one, one case of hypocalcified-hypoplastic, and one case of hypocalcified-hypoplastic-hypomaturation and in one case the type of amelogenesis imperfecta was not specified.

Considering the general diseases associated with amelogenesis imperfecta, these data were not mentioned in five articles while 6 patients were described as being free of general diseases, Nephrocalcinosis was diagnosed in one patient and two others suffered respectively from leukoderma and thyroid hyperfunction.

The patients' oral characteristics included dental sensitivity in 6 cases, periodontal diseases in 5 cases, caries in 5 cases, open bite in two cases and cross bite in one case. The loss of vertical dimension was described in 8 cases.

Concerning the methods of OVD evaluation, it was not mentioned in 7 patients,<sup>13,14,16,22,24,25</sup> while different methods were used in the other cases: the interocclusal distance was measured clinically and/or phonetically in 6 cases,<sup>15,17,18,19,20,21</sup> the esthetic considerations were evaluated in 2 cases,<sup>15,18</sup> a cephalometric analysis was conducted in 2 cases,<sup>19,21</sup> and a swallowing test was performed for one patient.<sup>21</sup> The characteristics of the patients included in the studies are described in Table 3.

- Treatment options (Table 4):** Occlusion vertical dimension was not modified in one case,<sup>28</sup> while it was modified in thirteen cases as follow: decreased

in one case,<sup>22</sup> and increased in 12 cases.<sup>16,17,18,19,20,21,23,24,25,26,27,28</sup> The treatment approaches were mainly associated with fixed prostheses.<sup>16,17,18,19,20,22,24,25,26,28</sup> Crown lengthening was described in five cases.<sup>16,17,22,24,26</sup> Esthetic veneers were mentioned in 5 cases: one was an hypocalcified type of AI, one was an hypomaturation and 3 cases were hypoplastic type of AI.<sup>19,22,28</sup> composite resin in 4 cases,<sup>16,19,20,23</sup>. Despite the fact that these adhesive treatment options should consider the enamel structure, authors did not take into consideration the type of AI and did not mention any unsealing in the follow up.

Occlusal splints were described in 4 cases<sup>17,20,24,28</sup> on lay in 2 cases,<sup>23, 27</sup> and removable denture in one case.<sup>21</sup>

Neither orthodontic treatments nor inlays were described.

The follow up of the cases was not always mentioned. It varied between 6 months and 5 years. Two criteria of success were used: esthetic improvement and patient satisfaction.

**Table 1: Numbers of titles listed in Pubmed (November 2014) for various combinations of the terms "Amelogenesis Imperfecta" and "Vertical dimension"**

Search terms	Citation	Reviews	RCTs
Vertical Dimension [Mesh]	4881	31	57
Amelogenesis Imperfecta [Mesh]	685	7	2
"Vertical Dimension"[Mesh] AND "Amelogenesis Imperfecta"[Mesh]	20	0	0

**Table 2: Rejected articles and cause of rejection**

Article	Cause of rejection
Hoods-Moonsammy et al., 2012	Narrative study
Pavlic et al., 2011	The treatment was not described by the authors
Luzzi et al., 2003	The OVD was not mentioned in the treatment
Bäckman and Adolfsson, 1994	The treatment was not described by the authors
Harley and Ibbetson, 1993	The date (<1994)
Bruziewicz-Mikłaszewska, 1978	The date (<1994)
Burzynski et al. 1973	The date (<1994)

**Table 3: Characteristics of the patients included in the selected articles**

Article	No. of patients	Gender	Age	Type of dentition	Type of AI	Associated general diseases	Associated oral characteristics	Methods of OVD 's evaluation
Harryparsad et al, 2013	1	Female	45 year old	Permanent dentition	Hypomaturation type	No disease	<ul style="list-style-type: none"> <li>- Periodontitis</li> <li>- Carious lesions</li> <li>- Missing teeth</li> <li>- Cross bite</li> <li>- Deep overbite (6mm)</li> </ul>	Interocclusal space (freeway space of 4 mm.)
Arnetzl and Arnetzl, 2011	1	Male	8 year old	Mixed dentition	Hypocalcified type	Not mentioned	<ul style="list-style-type: none"> <li>- Dental sensitivity</li> <li>- Loss of vertical dimension</li> </ul>	Not mentioned
Oliveira et al. 2011	1	Male	16-year-old	Permanent dentition	Hypocalcified type	-Leukoderma	<ul style="list-style-type: none"> <li>- Dental sensitivity</li> <li>- Gingivitis,</li> <li>- Calculus</li> <li>- Loss of vertical dimension</li> </ul>	Not mentioned
Chan et al., 2011	1	Female	40-year-old	Permanent dentition	Hypoplastic type	No disease	<ul style="list-style-type: none"> <li>- Dental sensitivity</li> <li>- Congenitally missing maxillary third molars</li> <li>- Caries</li> <li>- Reduced facial height</li> </ul>	esthetics and interocclusal space (freeway space of 5 mm.)
Assunção et al., 2009	1	Female	18-year-old	Permanent dentition	Hypocalcified hypoplastic type	Malnutrition during childhood and frequent Treatments with antibiotics	<ul style="list-style-type: none"> <li>- Loss of vertical dimension</li> </ul>	<ul style="list-style-type: none"> <li>- phonetics test</li> <li>- esthetics evaluation</li> <li>- interocclusal space</li> <li>- swallowing</li> </ul>
Sadighpour et al., 2009	1	Female	19-year-old	Permanent dentition	Hypoplastic type	<ul style="list-style-type: none"> <li>- Thyroid hyperfunction</li> </ul>	<ul style="list-style-type: none"> <li>- Caries</li> <li>- Gingival overgrowth</li> <li>- Anterior open bite</li> <li>- Missing teeth</li> </ul>	<ul style="list-style-type: none"> <li>- The interocclusal distance measured at the premolar region during physiological rest (was 2 mm.)</li> <li>- Cephalometric analysis</li> </ul>
Yip and Smales, 2003	2	Female	18-year-old	Permanent dentition	Hypoplastic Type	No diseases	<ul style="list-style-type: none"> <li>- Caries</li> <li>- Missing maxillary left canine.</li> </ul>	Not mentioned

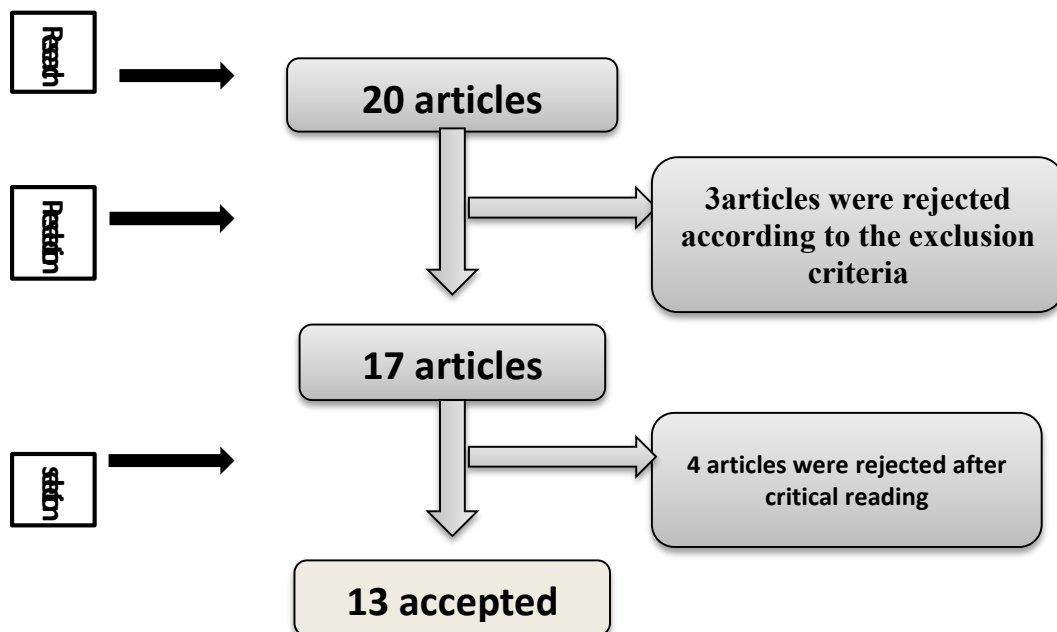
		Male	22-year-old	Permanent dentition	Hypoplastic type	No diseases	<ul style="list-style-type: none"> <li>- Caries</li> <li>- Malformed and delayed eruption of the second and third molars</li> <li>- Gingival recession/gingival overgrowth</li> <li>- Loss of vertical Dimension partly compensated by dento-alveolar growth.</li> </ul>	Not mentioned
Normand de la Tranchade et al, 2003	1	Female	15 year old	Mixed dentition	Hypomaturation, hypoplastic and hypocalcified type	Nephrocalcinosis	<ul style="list-style-type: none"> <li>- TMJ Dysfunction</li> <li>- follicular cysts</li> <li>- intracoronal resorption</li> <li>- delayed eruption</li> <li>- gingival enlargement</li> </ul>	Not mentioned
Sengun and Ozer, 2002	1	Male	14-year-old	Permanent dentition	Hypomaturation type	Not mentioned	<ul style="list-style-type: none"> <li>- Dental Sensitivity</li> <li>- Gingivitis</li> <li>- Loss of vertical dimension</li> </ul>	The interocclusal rest space
Williams and Becker, 2000	1	Female	16-year-old	Permanent dentition	Hypoplastic Genetic subtype	No diseases	<ul style="list-style-type: none"> <li>- Pathologic occlusion<sup>48</sup> unerupted</li> <li>- 38 absent</li> </ul>	- The interocclusal distance was measured clinically and by cephalometric analysis
Bouvier et al., 1999	1	Male	7-year-old	Mixed dentition	Not specified	Not mentioned	<ul style="list-style-type: none"> <li>- Dental Sensitivity</li> <li>- Loss of vertical dimension</li> </ul>	Not mentioned
Thompson and Schwartz, 1997	1	Male	23-year-old	Permanent dentition	Hypoplastic subtype D	No disease	<ul style="list-style-type: none"> <li>- Anterior and lateral skeletal open bite</li> <li>- Mild localized gingivitis</li> <li>- Caries</li> </ul>	The interocclusal distance was evaluated phonetically
Hunter and Stone, 1997	1	Male	9-year-old	Mixed dentition	Hypoplastic type	Not mentioned	<ul style="list-style-type: none"> <li>- Dental Sensitivity</li> <li>- Loss of vertical dimension</li> <li>- Deep overbite</li> </ul>	Not mentioned

**Table 4: Treatment options**

Treatment	Unmodified OVD	Modified OVD	
		Increased OVD	Decreased OVD
Fixed prosthesis	28a	16, 17, 18, 19, 20, 24, 25, 26, 28b	22
Veneers	28a	19, 28b	22
Removable prosthesis		21	
Resin composite		16, 18,19, 23	
Onlay		23, 27	
Crown lengthening		16, 17, 24,26	22
Occlusal splint		17, 20,24,28b	
Implant		17, 28b	

28a: first patient in the article

28b: second patient in the article

**Fig. 1: Diagram of selection of the articles**

## Discussion

Until now and considering the published papers on Medline, no systematic review has addressed the problem of the treatment of AI in terms of OVD.

The exploration of Medline identified 20 articles in this systematic review. Only 13 of them were selected after screening. The limited number of the selected papers could be related to (i) the rarity of the disease, or (ii) the complexity of treatments and the need for a long-term follow-up. Moreover, all the retained papers in this review were case reports. Although we failed to detect any interventional study in the literature, case reports are useful to share information on the patients, the pathology and the treatment in rare diseases such as AI in order to improve the treatment quality or the studies.

In the thirteen papers selected in this review, fourteen patients were described. Fifty percent of them were classified as hypoplastic, 14% as hypocalcified, 14% as hypomatured, 7% hypocalcified-hypoplastic, 7%

as hypocalcified-hypoplastic-hypomatured and the other cases were not specified. The hypoplastic form of AI is the most common type described in this review confirming previous data in the literature<sup>4</sup>.

Many authors have associated AI with several types of general diseases as a part of syndromes. These general diseases can affect either the kidney,<sup>29</sup> eyes,<sup>30</sup> nerves,<sup>31</sup> or skin.<sup>32</sup> In our study, general diseases were associated with AI in only three cases describing nephrocalcinosis<sup>16</sup>, dermatologic disorders as leukoderma,<sup>19</sup> and thyroid hyperfunction.<sup>22</sup> It is not clear from the literature whether the thyroid malfunction could be particularly attributed to a rare case of syndromic AI.

Although AI primarily affects the enamel formation, a variety of clinical implications may also be present, such as caries, attrition, excessive calculus deposition, and gingival hyperplasia.<sup>33</sup> In this review, periodontal diseases and caries were described in 5 cases. This could

be related to rough enamel surface and oral hygiene abilities occurring secondary to dental sensitivity.

Open bite malocclusion has been reported to be associated with AI. Indeed, through a clinical study, Ravassipour *et al.* stated that, among 54 AI patients, 42% of the affected individuals and 12% of the unaffected family members had dental or skeletal open bite malocclusion when compared to a general Caucasian population (5%). The etiology of this association has not been clarified. It could be explained by different factors such as abnormal eruption of posterior teeth, modified genes affecting both the dental and craniofacial developmental processes and environmental factors.<sup>34</sup>

In another study conducted by Backman and Adolfsson in 1994,<sup>12</sup> comparisons of cephalometric parameters between a group of children and adolescents with AI and a control group showed deviations indicating a skeletal open bite relation in the group with AI. The authors concluded that the vertical discrepancy seemed to accompany the most seriously affected cases of AI. In this review, open bite was described only in 2 cases of hypoplastic AI. This low number of cases with open bite could be due to the limited number of cases in this study and the lack of interest in skeletal diagnosis.

Regarding the dentition type in our study, 10 cases were in permanent dentition and 4 cases in mixed dentition. This could be attributed to the fact that the need to reestablish the vertical dimension of occlusion is more likely to be performed in permanent dentition than in temporary and mixed dentition.

Amelogenesis imperfecta is often complicated with reduced vertical dimension and increased interocclusal space due to the loss of tooth structure. Indeed, the loss of OVD was described in 8 cases.

While the methods of OVD evaluation are varied,<sup>35,36</sup> some papers have used one or two approaches such as the evaluation of interocclusal distance clinically and/or phonetically and the esthetic evaluation. Several other papers have not even explained how they evaluated the OVD. Only two articles have described an assessment of OVD via cephalometric analyses.<sup>22,24</sup>

To assess OVD, none of the proposed techniques have been proved to be scientifically accurate or superior to others.<sup>37</sup> Therefore, a cephalometric analysis, despite its imperfections, is considered as a reliable method of OVD diagnosis and a useful tool for the treatment plan.<sup>38</sup>

Treatment planning for patients with AI is conditioned by many factors such as age, type and severity of disorders. An interdisciplinary approach is necessary to evaluate, diagnose and resolve the esthetic and functional problems using a combination of prosthodontic, orthodontic and restorative treatment.

Regardless of the treatment modality, OVD is an important consideration for the treatment plan setting.

In this review, most cases were treated by modifying the OVD value. The increase was noted in 11 cases, however, in the 2 cases having an open bite, only one was treated with decreased OVD, while the other with

increased OVD which was justified by the authors to preserve dental tissues. It should be noted that the increase was performed in order to reestablish the correct OVD in 4 cases. This increase was performed over the correct OVD in 2 cases which was justified by prosthetics reasons; however, it was not specified in 5 cases. The value of the OVD variation was not mentioned in most cases. Yet, it is important to specify this value and to distinguish between the changes in the posterior and anterior levels. We note that this evaluation was neglected in most cases except one,<sup>24</sup> in which the conditions and protocol of OVD increase were detailed.

According to Orthlieb,<sup>39</sup> it is reasonable to assume that there is an optimal adaptive space concerning OVD and not a fixed point. So, it is possible to change OVD in both directions, increasing and decreasing. The key is to verify that the therapeutic OVD will be in harmony with all the anatomical and neuro-physiological determinants. Indeed, the preservation of an interocclusal space in resting posture and the lack of contact between the dental arches during the phonation are targets of therapeutic OVD. These targets are among others such as esthetics and lip competency.<sup>34</sup> These muscular references seem too variable to be reliable. The significant criteria that influence the decision are the following: esthetic and facial heights, skeletal mandibular morphology and typology, overjet and overbite, prosthetic space and TMJ and neuromuscular coordination.<sup>34,39</sup>

The therapeutic OVD should be validated through a temporary restoration or an occlusal splint. In this review, occlusal splint was used in 4 cases. In only one case, it was used at an increased OVD to assess the patient's response before starting oral rehabilitation.<sup>28</sup> In the other cases, it was used just to protect the ceramic prostheses,<sup>15,24</sup> or to perform full-mouth direct composite restorations.<sup>20</sup>

Regarding the rehabilitation of AI patients, various treatment modalities have been studied thanks to the advance in techniques and to the increased availability of dental materials. In the literature, the use of glass ionomer cements, composite resin veneers, porcelain veneers, stainless steel crowns, and over dentures are described in order to restore function and esthetics.

Most cases in this review were treated by prosthetic rehabilitation such as fixed full coverage prostheses, onlays and overdentures. However, composite resin restorations and cosmetic veneers were used in few cases, probably because of the insufficient bonding between the adhesive product and the enamel in AI reported in the literature.<sup>40</sup>

In our study, no unsealing was described in the cases treated by composite resin or veneers. This could be due to the scarcity of the cases, the short period of follow up and the lack of clinical randomized controlled trials in this topic.

## Conclusion

- Amelogenesis imperfecta (AI) is a genetic disorder that causes defective enamel development resulting in active tooth wear that could affect the vertical dimension of occlusion (OVD).
- The treatment options should consider OVD in order to restore esthetics and function.
- According to our study, it seems to be important to explore OVD systematically in AI for the treatment plan setting.
- Adhesive treatments represent an interesting option for AI patients. However, full coverage restorations may be a more effective method to provide maximal protection against dentinal sensitivity, to improve esthetics and to restore functions.
- Studies of high level of evidence such as clinical randomized controlled trials are needed to better evaluate the efficiency of adhesive treatment with AI patients in the long term.
- It is recommended to:
  - Evaluate OVD with the available methods.
  - Record jaw relationship in the centric relation at the correct OVD.
  - To produce Diagnostic wax up on the mounted study cast.
  - To realize provisional restorations.
  - To review the patient's adaptability to the new occlusion by the absence of temporo-mandibular joint muscle mastication abnormalities.
  - To finally rehabilitate the patient at the validated OVD.

## Acknowledgement

Authors acknowledge the Tunisian Association for Dental Research for the supervising of the study. They also thank Pr Samir Boukattaya for his help.

## References

1. Yamashita S, Shimizu M, Katada H. A Newly Proposed Method to Predict Optimum Occlusal Vertical Dimension. *J Prosthodont*. 2014 ;22 :1-4.
2. Abduo J, Lyons K. Clinical considerations for increasing occlusal vertical dimension: a review. *Aust Dent J* 2012;57:2-10.
3. Kois JC1, Phillips KM. Occlusal vertical dimension: alteration concerns. *Compend Contin Educ Dent* 1997;18:1169-1174.
4. Bäckman B, Holm AK. Amelogenesis imperfecta: prevalence and incidence in a northern Swedish county. *Community Dent Oral Epidemiol*1986;14:43-47.
5. Witkop CJ. Clinical aspects of dental anomalies. *Int Dent J*1976;26:378-390.
6. Nusier M, Yassin O, Hart TC, Samimi A, Wright JT. Phenotypic diversity and revision of the nomenclature for autosomal recessive amelogenesis imperfecta. *Oral Surg Oral Med Oral Pathol Oral Radiol Endod* 2004;97:220-230.
7. Poulsen S, Gjørup H, Haubek D, Haukali G, Hintze H, Løvschall H, Errboe M. Amelogenesis imperfecta - a systematic literature review of associated dental and orofacial abnormalities and their impact on patients. *Acta Odontol Scand* 2008;66:193-199.
8. Aren G, Ozdemir D, Firatli S, Uygur C, Sepet E, Firatli E. Evaluation of oral and systemic manifestations in an amelogenesis imperfecta population. *J Dent* 2003;31:585-591.
9. Burzynski NJ, Gonzalez WE Jr, Snawder KD. Autosomal dominant smooth hypoplastic amelogenesis imperfecta. Report of a case. *Oral Surg Oral Med Oral Pathol* 1973;36:818-823.
10. Bruziewicz, Miklaszewska B. A case of hereditary amelogenesis imperfecta treated prosthetically. *Protet Stomatol* 1978; 28:127-130.
11. Harley KE, Ibbetson RJ. Dental anomalies--are adhesive castings the solution?. *Br Dent J* 1993;174:15-22.
12. Bäckman B, Adolffson U. Craniofacial structure related to inheritance pattern in amelogenesis imperfecta. *Am J Orthod Dentofacial Orthop* 1994;105:575-582.
13. Luzzi V, Bossù M, Cavallè E, Ottolenghi L, Polimeni A. Case report: clinical management of hypoplastic amelogenesis imperfecta. *Eur J Paediatr Dent* 2003 ;4:149-154.
14. Pavlic A, Battelino T, Trebusak, Podkrajsek K, Ovsenik M. Craniofacial characteristics and genotypes of amelogenesis imperfecta patients. *Eur J Orthod* 2011;33:325-331.
15. Hoods-Moonsammy VJ, Mothopi MM, Taruvingira AK, Owen CP, Howes DG. Prosthodontic management of patients with Amelogenesis Imperfecta. *SADJ* 2012,67:409-412.
16. Normand de la Tranchade I, Bonarek H, Marteau JM, Boileau MJ, Nancy J. Amelogenesis imperfecta and nephrocalcinosis: a new case of this rare syndrome. *J Clin Pediatr Dent* 2003;27:171-175.
17. Harryparsad A, Rahman L, Bunn BK. Amelogenesis imperfecta: a diagnostic and pathological review with case illustration. *SADJ*. 2013 Oct;68(9):404-407. Review.
18. Arnetzl GV, Arnetzl G. Adhesive techniques and machineable high-performance polymer restorations for amelogenesis imperfecta in mixed dentition. *Int J Comput Dent* 2011,14:129-138.
19. Oliveira IK, Fonseca Jde F, Amaral FL, Pecorari VG, Basting RT, França FM. Diagnosis and esthetic functional rehabilitation of a patient with amelogenesis imperfecta. *Quintessence Int* 2011;42:463-469.
20. Chan KH, Ho EH, Botelho MG, Pow EH. Rehabilitation of amelogenesis imperfecta using a reorganized approach: a case report. *Quintessence Int* 2011;42:385-391.
21. Assunção GW, Delben J, Barao V. Overdenture as a Restorative Option for Hypocalcified-hypoplastic Amelogenesis imperfecta: A Case Report. *The journal of contemporary dental practice* 2009,03:1-8.
22. Sadighpour L, Geramipannah F, Nikzad S. Fixed rehabilitation of an ACP PDI class III patient with amelogenesis imperfecta. *J Prosthodont* 2009;18:64-70.
23. Sengun A, Ozer F. Restoring function and esthetics in a patient with amelogenesis imperfecta: a case report. *Quintessence Int* 2002;33:199-204.
24. Williams WP, Becker LH. Amelogenesis imperfecta: functional and esthetic restoration of a severely compromised dentition. *Quintessence Int* 2000; 31:397-403.
25. Bouvier D, Duprez JP, Pirel C, Vincent B. Amelogenesis imperfecta-a prosthetic rehabilitation: A clinical report. *J Prosthet Dent* 1999;82:130-131.
26. Thompson GA, Schwartz JM. Oral rehabilitation of a patient with amelogenesis imperfect. *J Prosthodont* 1997;6:257-264.

27. Hunter L, Stone D. Supraoccluding cobalt-chrome onlays in the management of amelogenesis imperfecta in children: a 2-year case report. *Quintessence Int* 1997;28:15-19.
28. Yip HK, Smales RJ. Oral rehabilitation of young adults with amelogenesis imperfecta. *Int J Prosthodont* 2003;16:345-349.
29. Rajathi JM, Austin RD, Mathew P. McGibbon Syndrome: a report of three siblings. *Indian. J Dent Res* 2013;24:511-514.
30. Luder HU, Gerth-Kahlert C, Ostertag-Benzinger S, Schorderet DF. Dental phenotype in Jalili syndrome due to a c.1312 dupC homozygous mutation in the CNNM4 gene. *PLoS One* 2013;8.
31. González-Arriagada WA, Carlos-Bregni R, Contreras E, Almeida OP, Lopes MA. Kohlschütter-Tönz Syndrome. Report of an additional case. *J ClinExp Dent* 2013;5:108-111.
32. Javed AP, Shenai P, Chatra L, Veena KM, Rao PK, Prabhu R. Occurrence of epidermolysisbullosa along with Amelogenesis imperfecta in female patient of India. *Dent Res J (Isfahan)* 2013;10:813-816.
33. Markovic D1, Petrovic B, Peric T. Case series: clinical findings and oral rehabilitation of patients with amelogenesis imperfecta. *Eur Arch Paediatr Dent*. 2010;11:201-208.
34. Ravassipour DB, Powell CM, Phillips CL, Hart PS, Hart TC, Boyd C, Wright JT. Variation in dental and skeletal open bite malocclusion in humans with amelogenesis imperfecta. *Arch Oral Biol* 2005;50:611-623.
35. Orthlieb JD, Laurent M, Laplanche O. Cephalometric estimation of vertical dimension of occlusion. *J Oral Rehabil* 2000;27:802-807.
36. Toolson LB, Smith DE. Clinical measurement and evaluation of vertical dimension. *J Prosthet Dent* 2006;95:335-339.
37. Fayz F1, Eslami A. Determination of occlusal vertical dimension: a literature review. *J Prosthet Dent*. 1988 ;59:321-323.
38. Tavano KT, Seraidarian PI, de Oliveira DD, Jansen WC. Determination of vertical dimension of occlusion in dentate patients by cephalometric analysis-pilot study. *Gerodontology* 2012;29:297-305.
39. Rebibo. M, Darmouni. L, Jouvin. J, Orthlieb. J. D. Vertical dimension of occlusion: the keys to decision we may play with the VDO if we know some game's rules. *J. Stomat. Occ. Med* 2009;2:147-159.
40. Seow WK, Amaratunge A. The effects of acid-etching on enamel from different clinical variants of amelogenesis imperfecta: an SEM study. *Pediatr Dent* 1998;20:37-42.