



## Case Report

# Diagnostic dilemmas and multidisciplinary management of glandular odontogenic cyst: A case report

Suhailath Aslam<sup>1\*</sup>, Shabna Moyin<sup>1</sup>, Vishnudas Pravish<sup>1</sup>, Sunil PM<sup>1</sup>, Arun Kumar<sup>1</sup>

<sup>1</sup>Dept. of Conservative Dentistry, Sree Anjaneya Institute of Dental Sciences, Modakkallur, Kerala, India



### ARTICLE INFO

#### Article history:

Received 25-08-2024

Accepted 20-09-2024

Available online 14-10-2024

#### Keywords:

Glandular odontogenic cyst

Anterior maxilla

Histopathologic diagnosis

Surgical management

Recurrence prevention

### ABSTRACT

Glandular odontogenic cyst (GOC) is a rare odontogenic cyst typically found in the anterior mandible and, in rare cases, the anterior maxilla, characterized by asymptomatic, slow-growing swelling. It mimics other odontogenic cysts and tumors, complicating the diagnosis. Histologically, GOC features mucus-producing cells and gland-like structures, initially suggesting a salivary gland origin. However, the absence of salivary gland markers and the presence of hybrid lesions with other odontogenic tumors confirm its odontogenic nature. Known for its aggressive behavior, GOC can cause significant growth and bone perforation, leading to high recurrence rates. This case report discusses a 34-year-old male with a recurrent cystic lesion initially misdiagnosed as a periapical abscess. Accurate diagnosis and successful management involved root canal treatment and surgical intervention, highlighting the importance of precise diagnosis and prompt treatment.

This is an Open Access (OA) journal, and articles are distributed under the terms of the [Creative Commons Attribution-NonCommercial-ShareAlike 4.0 License](https://creativecommons.org/licenses/by-nc-sa/4.0/), which allows others to remix, tweak, and build upon the work non-commercially, as long as appropriate credit is given and the new creations are licensed under the identical terms.

For reprints contact: [reprint@ipinnovative.com](mailto:reprint@ipinnovative.com)

## 1. Introduction

The glandular odontogenic cyst (GOC) is a rare and aggressive odontogenic cyst. Most of the GOCs reported in the literature are asymptomatic, with the majority in the mandible (70%) rather than the maxilla (30%).<sup>1</sup> It often reaches significant proportions and exhibits high recurrence rates. Initially described by Padayachee and Van Wyk in 1987<sup>2</sup> as a "sialo-odontogenic cyst," Gardner et al. later characterized it as a unique clinicopathologic entity, coining the term "glandular odontogenic cyst" due to its odontogenic epithelial lining.<sup>3</sup> It was first added to the World Health Organization's (WHO) odontogenic tumor classification in 1992, with the designation of "glandular odontogenic cyst" or sialo-odontogenic cyst.<sup>4</sup> The last WHO classification, in 2017,<sup>4</sup> classified the GOC as a developmental cyst with epithelial features that simulate salivary gland or glandular differentiation.<sup>4</sup> GOC presents as a painless, slow-growing

mass and predominantly affects individuals in their fourth and fifth decades, with a higher incidence in males.<sup>5</sup>

Radiographically, GOC appears as a unilocular or multilocular radiolucency with well-defined and scalloped borders. This radiographic appearance can mimic other conditions, including odontogenic keratocyst, aneurysmal bone cyst, low-grade mucoepidermoid carcinoma, ameloblastoma, central giant cell granuloma, and radicular cyst.<sup>6</sup> The radiological findings of GOC are not distinct from those of other odontogenic cysts or central mucoepidermoid carcinoma, making histopathological examination essential for accurate differentiation.<sup>7</sup> Histologically, GOC features mucus-producing cells and gland-like structures, initially suggesting a salivary gland origin. However, the absence of salivary gland markers and the presence of hybrid lesions with other odontogenic tumors confirm its odontogenic nature.

Treatment of GOC typically involves curettage, enucleation, and peripheral ostectomy of the surgical site.

\* Corresponding author.

E-mail address: [suhailathpp@gmail.com](mailto:suhailathpp@gmail.com) (S. Aslam).

Due to its aggressive nature and potential for recurrence, more extensive surgical interventions, such as jaw resection followed by long-term follow-up, are often recommended.<sup>8</sup> This case report presents a GOC in the anterior maxilla of an adult male, managed with root canal treatment, cyst enucleation, peripheral ostectomy, and apicectomy. It underscores the importance of comprehensive diagnosis and early intervention to prevent recurrence.

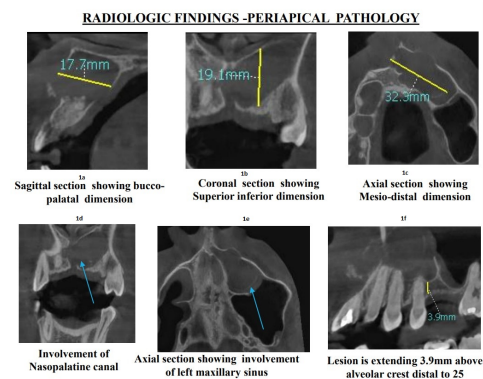
## 2. Case Presentation

A 34-year-old male presented with mild pain and swelling in his upper front teeth, persisting for several years. He had a traumatic fall 12 years ago, fracturing his front teeth, which were restored. Four years later, he experienced pain and swelling in the same area and began, but did not complete, root canal treatment. This issue recurred after three years, leading to another root canal attempt and surgical intervention, including curettage and apicectomy. Despite these efforts, swelling recurred. Examination revealed no facial asymmetry, intraoral swelling, or sinus opening. Teeth 21, 22, and 23 showed yellowish discoloration, with a slight displacement of teeth 21 and 22. The cold test was negative for tooth 23.

Routine radiographic examination revealed root canal-treated teeth 21 and 22 with a large cystic lesion. On CBCT, the size of the lesion was approximately 32.3 mm (M-D) x 19.1 mm (sup Inf) x 17.7 mm (B-P). A solitary, ill-defined, osteolytic, variably corticated, hypodense large periapical lesion is observed in the anterior maxillary region. The lesion extends mesiodistally from the distal aspect of tooth 11 at its apical third to the distal aspect of tooth 23. Superiorly, the lesion extends from the floor of the nasal cavity, and inferiorly, it reaches up to 3.9 mm above the alveolar crest.

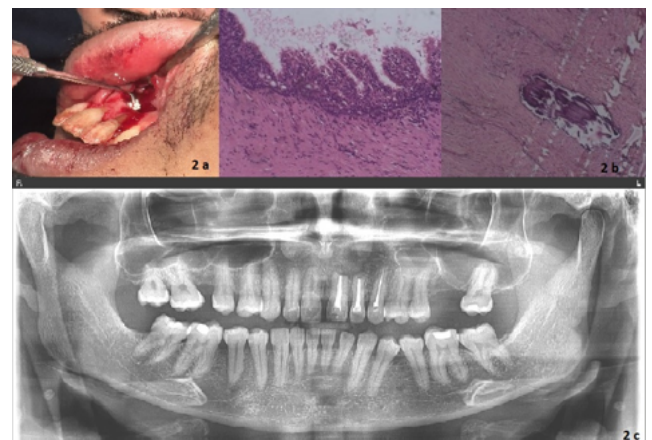
CBCT revealed a large unilocular cystic lesion in the anterior hard palate, causing buccal and palatal expansion, bicortical perforation, nasopalatine canal effacement, and left maxillary sinus involvement (Figure 1). Blunt apices in teeth 21 and 22 indicated previous apicectomy, and tooth 23 showed external root resorption. The provisional diagnosis was a recurring periapical abscess in the root canal-treated 21, 22, and 23 regions, with an infected radicular cyst as a differential diagnosis. A biopsy and histopathologic correlation were advised for confirmation.

Teeth 21 and 22 underwent re-root canal treatment, and tooth 23 received a root canal treatment. Due to continuous fluid discharge from tooth 2, an open dressing was given for one day. Intra canal medicaments, including calcium hydroxide with 2% chlorhexidine, Metapex, and triple antibiotic paste, were used to disinfect the canals. An intraoral sinus tract with fluid discharge indicated a persistent infection at tooth 21. Teeth 22 and 23 were successfully obturated; mid-surgical obturation was required for tooth 21 due to ongoing fluid leakage. Local



**Figure 1:** Radiologic findings periapical pathology **a:** Sagittal section showing bucco palatal dimension **b:** Coronal section showing superior inferior dimension **c:** Axial section showing mesio distal dimension **d:** Involvement of Nasopalatine Canal **e:** Axial section showing involvement of left maxillary sinus **f:** Lesion is extending 3.9 mm above alveolar crest distal to 25

anesthesia was administered for cyst enucleation, followed by an incision to remove the cyst. Peripheral ostectomy, apicectomy, retrograde filling with MTA, and suturing were performed (Figure 2 a). The specimen was sent for biopsy.



**Figure 2:** a) Apicectomy procedure; b) Histopathology; c) Follow up radiograph with successful healing and new bone formation throughout the surgical site

The histological examination revealed features indicative of a glandular odontogenic cyst (GOC). The cyst was lined with non-keratinized squamous epithelium, exhibiting a flat interface and showing the presence of spherules, knobs, or whorls. There was focal luminal proliferation, hob-nail cells, and mucous/goblet cells with intraepithelial mucous pools. Additionally, intraepithelial glandular microcystic or

duct-like structures and lining epithelium with papillary proliferation were observed (Figure 2 b). These findings are consistent with the diagnosis of GOC. Regular follow-ups at 1, 3, 6 months, and 1 year showed steady healing of the periapical lesion, with neobone forming in the cystic area and the patient remaining symptom-free throughout, as confirmed by successful healing and new bone formation throughout the surgical site seen on the panoramic radiograph (Figure 2 c). This consistent progress highlights successful treatment and robust bone regeneration. There were no signs of recurrence, and the patient was found to be healthy. The involved teeth were functional and in good condition.

### 3. Discussion

Glandular odontogenic cysts (GOCs) are rare and distinctive cystic lesions within the jawbones. These cysts are noteworthy for their aggressive nature, substantial growth potential, and high recurrence rates, which pose significant challenges in both diagnosis and management. The term "glandular odontogenic cyst" was coined by Gardner et al.<sup>2</sup> reflecting its unique histopathologic features, although it was initially described by Padayachee and Van Wyk in 1987 as a "sialo-odontogenic cyst".<sup>3</sup> The prevalence of GOCs is low, ranging from 0.012% to 1.3%, with an average of 0.17% of all jaw cysts. This rarity contributes to the diagnostic difficulties, as GOCs can mimic other odontogenic cysts and tumors both clinically and radiographically.<sup>8</sup>

Most lesions present a unilocular radiographic appearance (61.5%), are commonly related to bone expansion (73%), cortical perforation, tooth displacements, and even root resorption.<sup>9</sup> Histologically, GOCs are characterized by several major criteria: non-keratinized squamous epithelial lining with a flat interface; spherules, knobs, or whorls; focal luminal proliferation; hob-nail cells; mucous/goblet cells with intraepithelial mucous pools; and intraepithelial glandular microcystic or duct-like structures. Additionally, minor criteria that support the diagnosis include lining epithelium with papillary proliferation, ciliated cells, multicystic or multiluminal architecture, and clear or vacuolated cells in the basal or spinous layers. These histopathologic criteria help distinguish GOCs from other cystic lesions and tumors.

The aggressive behavior of GOCs and their potential for recurrence require careful treatment consideration. Management strategies include conservative and aggressive approaches. Conservative methods involve marsupialization, enucleation, and curettage, with or without peripheral ostectomy. Marsupialization creates a surgical window for drainage and size reduction, suitable for smaller lesions or critical anatomical locations. Enucleation is the complete surgical removal of the cyst, typically for

smaller, well-defined lesions. Curettage scrapes out the cyst lining, while peripheral ostectomy removes a thin layer of surrounding bone to ensure complete eradication of cystic cells and reduce recurrence risk.

Aggressive management is reserved for larger or recurrent GOCs. This includes marginal resection and segmental jaw resection. Marginal resection involves removing the cyst along with a margin of healthy bone to ensure complete removal and minimize the chance of recurrence. Segmental jaw resection is a more extensive procedure involving the removal of a segment of the jaw containing the cyst. This approach is typically used for very large or recurrent cysts and aims to provide a definitive solution while considering the functional and aesthetic impacts on the patient. The increased recurrence rates can be due to its intrinsic biological behavior, multilocularity of the cyst, and incomplete removal of the lining following conservative treatment. The choice between conservative and aggressive management depends on the cyst's size, location, patient's age, and potential for recurrence.<sup>10</sup>

Arora G. reported a case of a glandular odontogenic cyst in the anterior maxilla, where complete enucleation resulted in no recurrence after one year of follow-up.<sup>11</sup> This case highlights the importance of thorough management and long-term monitoring to prevent recurrence in GOC cases. Long-term follow-up studies are essential to monitor for recurrence and assess the efficacy of various treatment modalities. The ongoing evaluation and refinement of management strategies will be crucial in ensuring optimal outcomes for patients with this rare and challenging cystic lesion.

### 4. Conclusion

Case reports play a crucial role in advancing medical knowledge, particularly for rare conditions like glandular odontogenic cysts (GOCs). This case of a 34-year-old male, treated with root canal therapy, cyst enucleation, peripheral ostectomy, and apicectomy, underscores the importance of accurate diagnosis and tailored treatment. Sharing insights into successful management and outcomes helps guide clinicians in similar cases. Keeping updated with the latest research and guidelines ensures practitioners provide the best care. Continuous evaluation and adherence to evolving practices enhance the ability to effectively diagnose, treat, and manage GOCs, improving patient outcomes and healthcare quality.

### 5. Conflict of Interest

None.

### 6. Source of Funding

None.

## References

1. Fowler CB, Brannon RB, Kessler HP, Castle JT, Kahn MA. Glandular odontogenic cyst: analysis of 46 cases with special emphasis on microscopic criteria for diagnosis. *Head Neck Pathol.* 2011;5(4):364–75.
2. Padayachee A, Van Wyk C. Two cystic lesions with features of both the botryoid odontogenic cyst and the central mucoepidermoid tumour: sialo-odontogenic cyst? *J Oral Pathol.* 1987;16(10):499–504.
3. Gardner DG, Kessler HP, Morency R, Schaffner DL. The glandular odontogenic cyst: an apparent entity. *J Oral Pathol.* 1988;17(8):359–66.
4. Vered M, Wright JM. Update from the 5th Edition of the World Health Organization Classification of Head and Neck Tumors: Odontogenic and Maxillofacial Bone Tumours. *Head and Neck Pathol.* 2022;16(1):63–75.
5. De Campos W, Araújo R, Martin V, Trierveiler M, Gomes P, Lemos CA. Glandular Odontogenic Cyst in the Anterior Mandible: A Case Report of a Conservative Approach and a Recurrence Detection. *Diagnosics (Basel).* 2023;13:1452.
6. Immanuel J, Krishnan R. Clinicopathological comparison of periapical cyst and periapical granuloma in a cohort of Tamil population. *J Conserv Dent Endod.* 2024;27(5):524–8.
7. Modi K, Padmapriya R, Elango S, Khandelwal P, Arul B, Natanasabapathy V. Nonmalignant nonendodontic lesions mimicking periapical lesions of endodontic origin: A systematic review. *J Conserv Dent.* 2022;25(3):214–25.
8. Macdonald-Jankowski DS. Glandular odontogenic cyst: systematic review. *Dentomaxillofac Radiol.* 2010;39(3):127–39.
9. Martins-Chaves RR, Granucci M, Gomez RS, Henriques de Castro, W. Glandular Odontogenic Cyst-A Case Series. *J Oral Maxillofac Surg.* 2021;79(5):1062–8.
10. Mascitti M, Santarelli A, Sabatucci A, Procaccini M, Muzio L, Zizzi L, et al. Glandular odontogenic cyst: review of literature and report of a new case with cytokeratin-19 expression. *Open Dent J.* 2014;8(1-2):1–12.
11. Arora G, Kumar J, Singh M, Kumar S. Glandular Odontogenic Cyst of Anterior Maxilla - A Rare Case Report. *Ann Maxillofac Surg.* 2021;11(2):321–4.

## Author biography

**Suhailath Aslam**, Post Graduate Student

**Shabna Moyin**, Professor

**Vishnudas Pravish**, Reader

**Sunil PM**, Professor

**Arun Kumar**, Post Graduate Student

**Cite this article:** Aslam S, Moyin S, Pravish V, Sunil PM, Kumar A. Diagnostic dilemmas and multidisciplinary management of glandular odontogenic cyst: A case report. *International Dental Journal of Student's Research* 2024;12(3):153-156.