



Original Research Article

Oral and perioral piercings: Awareness and knowledge among undergraduate dental students in a private dental college, Haryana

Reshma RK^{1,*}, Sumit Bhateja¹, Tamanna Soni¹, Geetika Arora², Sheena T Arora¹, Vineeta Charan¹

¹Dept. of Oral Medicine and Radiology, Manav Rachna Dental College, Faridabad, Haryana, India

²Dept. of Public Health Dentistry, Inderprastha Dental College & Hospital, Ghaziabad, Uttar Pradesh, India



ARTICLE INFO

Article history:

Received 19-08-2021

Accepted 30-09-2021

Available online 16-10-2021

Keywords:

Oral piercing
perioral piercing
complications

ABSTRACT

Background: Oral and perioral piercings are now commonly seen in young adults leading to various types of complications. Undergraduate dental students are the most immediate group with peers belonging to this age criteria thus their knowledge regarding oral piercings and related complications is of utmost concern.

Aim: The present study was conducted among undergraduate dental students in a private dental college in Haryana to determine the knowledge and awareness of oral and perioral procedures and their complications.

Materials and Methods: A closed ended questionnaire was circulated online using Google forms. Total 145 dental undergraduate students of a private college participated in this survey. Total 10 questions were asked from the students and the data was then presented in form of pie charts and bar diagrams.

Result: The subjects had a fair knowledge and awareness about oral and perioral piercing procedures and their associated complications. Only 71.6% responded that there exists complications and many students were unaware of the fact that gingival recession, Ludwig's angina, endocarditis etc. are some serious complications which result as a sequelae of such piercings. Moreover only 72% students had familiarity that oral hygiene practices changes after getting oral piercing and rest were unfamiliar with this truth.

Conclusion: These undergraduate students had a decent awareness and knowledge about the oral and perioral piercings. But as oral and perioral piercings have potential oral health hazard, we wish to recommend that it should be not encouraged and request the dental fraternity to discourage the same.

This is an Open Access (OA) journal, and articles are distributed under the terms of the [Creative Commons Attribution-NonCommercial-ShareAlike 4.0 License](https://creativecommons.org/licenses/by-nc-sa/4.0/), which allows others to remix, tweak, and build upon the work non-commercially, as long as appropriate credit is given and the new creations are licensed under the identical terms.

For reprints contact: reprint@ipinnovative.com

1. Introduction

Piercing is a worldwide form of body art and has become increasingly popular in western society.¹ Piercing refers to the infiltration of the jewellery into the body areas such as the eyebrows, ears, tongue, nose, lips, navel and genitals. Oral and perioral piercing has been practiced for a long time for various religious, cultural, sexual or identical reasons and has been believed and practiced autonomously all over the world.² With today's fast-growing generation, a desire for distinctive identity is

the main factor responsible for such piercings.^{1,2} Lately oral piercings has gained popularity among teens and young adults. Self-representation in these age groups has increased significantly and they go towards extreme to get desired results. Other contributing factors are daring behaviour, independence of spirit and enhancing the body as per the fashion.^{3,4} In oral cavity tongue piercing is the most common, followed by lips. Piercing has entered a new sphere involving other areas such as frennum, uvula, philtrum, cheeks and even tongue splitting. Frequently used jewelry for such piercings are barbell, studs, labret, captive beads, rings etc.¹⁻⁵

* Corresponding author.

E-mail address: reshmark0498@gmail.com (Reshma RK).

Even though individuals succeed in expressing themselves, but many of them are unaware of the associated risks. It is important to know that oral and perioral piercings not only affect oral health, but also cause other long-term systemic damage if not treated with care.⁶ Many local and systemic complications have been observed as a consequence of oral and perioral piercing which include;

1.1. Immediate complication

1. Edema of the tongue leading to airway obstruction, pain of tongue affects speech, mastication and deglutition.^{7,8}
2. Anaphylactic reactions can be caused by some of the materials e.g., nickel.^{9,10}
3. Hyper salivation, puncturing the tissues without proper measures can cause severe hemorrhage
4. Trigeminal nerve damage: inferior alveolar and superior alveolar are commonly involved, lingual nerve damage usually seen in tongue piercings.^{8,9,10}
5. Aspiration of jewelry during the uvula piercing or tongue piercing, can lead to choking and death of the patient.¹¹

1.2. Delayed complication

1. Ulcerations
2. Plaque accumulation can produce halitosis and possible infections.¹²
3. Endocarditis is the most common and potentially due to *Neisseria mucosa* and *Haemophilus aphrophilus*.¹³⁻¹⁵
4. Trauma to lingual gingiva, erythema and edema of gingiva due to rubbing the ball in the lingual gingiva.¹⁶
5. Periodontal attachment loss involving proximal teeth.¹⁶⁻¹⁸
6. Ludwig's angina usually due to frenulum and lingual piercing.¹⁹
7. Hyperplastic tissue formation.^{20,21}
8. Dehiscence especially in mandibular anterior.^{22,23}
9. Fracture of the tooth occur by biting the barbell, careless jewelry insertion, talking, eating etc.²⁴⁻²⁶
10. If tongue piercing goes wrong, bifid tongue can be a serious complication.²⁷
11. Gingival recession due to continuous friction of the gingiva with the jewellery.^{28,29}
12. Pulpal sensitivity from contact between galvanic currents in stainless steel ornaments and other intra-oral jewellery.^{9,19}
13. Radiopacity of piercing jewelry is seen during X-ray examinations. Hence for panoramic X-rays, removing metal objects above the neck is a must.¹¹
14. Most dangerous oral site for piercing is the uvula, due to the increased chances of airway obstruction. It has been found that piercing is a potential route for the

transmission of viruses such HIV, hepatitis (B, C, D and G), herpes simplex and Epstein-Barr.³⁰

15. They have mentioned congenital deformities and the possibility of cerebellar abscesses.³¹

As dental students, it is the responsibility of each and every student to educate their peer groups as well as the patients about the effect of piercing and how it acts as a double edge sword.

2. Materials and Methods

The present study is a questionnaire based survey on the awareness of complications related to oral and perioral piercing which was conducted online using Google forms. In total 145 undergraduate students of a private dental college Haryana participated in this survey. A total of 10 questions were asked from the participants. The participants replied to the survey by clicking appropriate options. The questionnaire was self- conceptualized and its authenticity was made by discussing it with faculty of the department of Oral Medicine and Radiology. The survey was approved by institutional ethical committee. After the data collection, it was compiled and presented in the form of pie charts and bar diagrams.

2.1. Inclusion criteria

1. Undergraduate dental students belonging to the age group of 19-22 years
2. Region- Haryana.

2.2. Exclusion criteria

1. Faculty, PG students and Interns.

3. Results

A total of 145 subjects participated in the study and the data was evaluated with pie charts and bar diagrams.

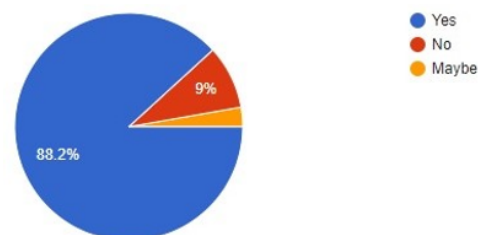


Fig. 1: Have you ever heard of or seen oral and perioral piercing?

88.2% have heard or seen oral and perioral piercing, 9% have never seen or heard of oral and perioral piercing and 2.8% responded with maybe.

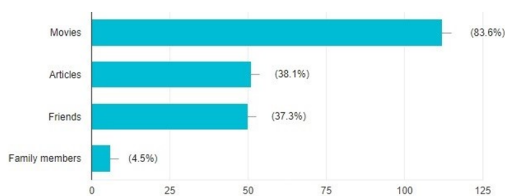


Fig. 2: If yes then from where? 83.6% said they saw it in movies 38.1% read it in articles 37.3% heard it from friends and 4.5% from family members.

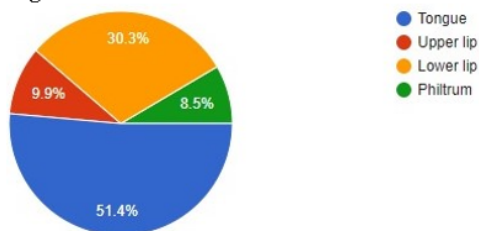


Fig. 3: What is the most common site? 51.4% responded with most common site as tongue 30.3% said lower lip 9.9% said upper lip 8.5% responded as philtrum.

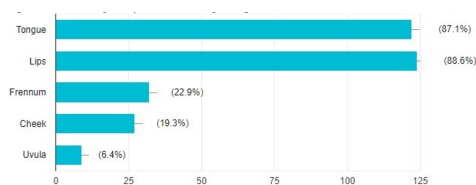


Fig. 4: Click on the options you think are the piercing sites. As far as the knowledge of other piercing sites are concerned only 6.4% knew that uvula is also pierced 19.3% knew about cheek 22.9% knew about frennum 88.6% about lips and 87.1% about tongue.

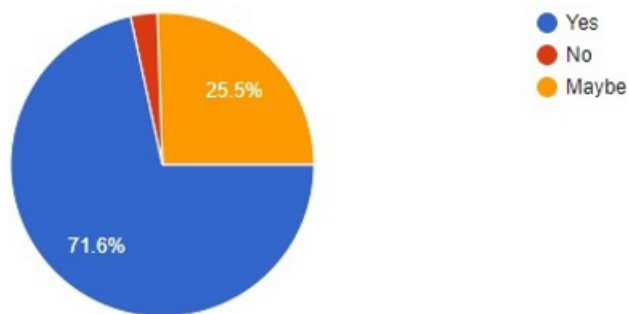


Fig. 5: Do you think there occurs any complications after oral and perioral piercing is done? While enquiring about the complication, 71.6% responded as yes that there exist complications related oral and perioral piercing 25.5% responded as maybe and 2.8% didn't know about the complications.

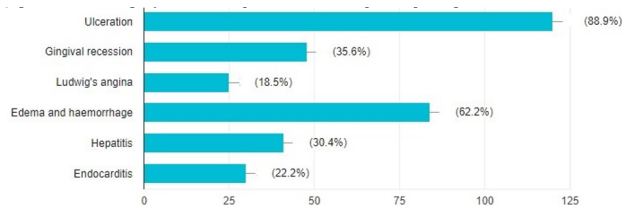


Fig. 6: What according to you are the complications of oral and perioral piercing? 88.9% knew ulceration as a complication 62.2% knew about edema and hemorrhage. 35.6% had a knowledge about gingival recession 30.4% were aware of hepatitis 22.2% knew about endocarditis and only 18.5% were familiar about Ludwig's angina.

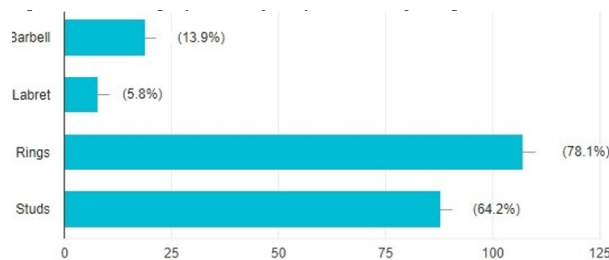


Fig. 7: What according to you are the jewelry used for oral piercing? 78.1% were familiar with ring as an oral piercing jewellery 64.2% recognized stud as an oral piercing jewellery 13.9% identified barbell as jewellery and only 5% knew about labret.

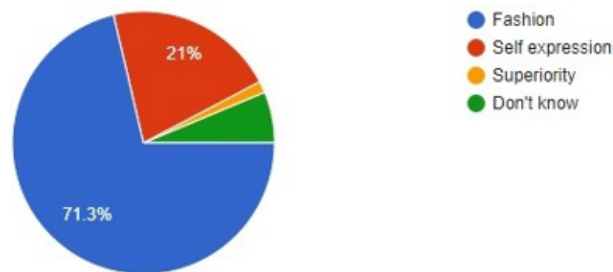


Fig. 8: Why do you think people get their oral and perioral piercings done? 71.3% considered oral piercing as a fashion statement 21% believed it as a self-expression 1.4% regarded it as superiority and 6.3% didn't know why people perform oral piercing.

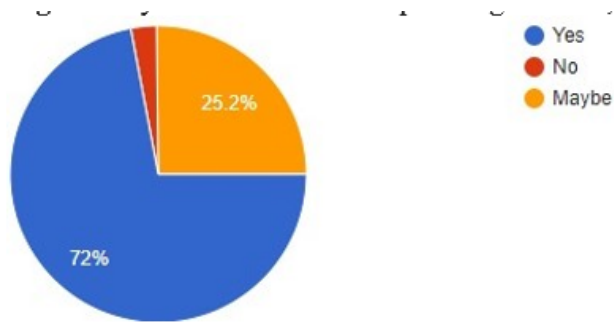


Fig. 9: Do you think once oral piercing is done, there will be any change in oral hygiene methods? 72% believed that there will be change in oral hygiene practice 25.2% responded with maybe and only 2.8% said there will be no change.

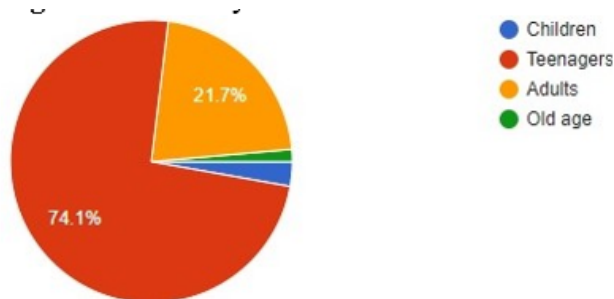


Fig. 10: What do you think is the most common age group that goes for oral piercings? 74.1% presume that teenagers are most commonly involved with oral piercings 21.7% responded that adults do it 2.8% answered as children and 1.4% old age.

4. Discussion

Oral and perioral piercing is just an ill wind that blows nobody any good. These piercings are performed in tattoo studios. Many of the piercers are not even licensed practitioners and thus piercing procedures are done without even giving appropriate anesthesia.^{7,19} Some of them use the same needles to different person frequently without sterilization. Hence, various piercing failure cases have been reported worldwide. In fact, American Dental Association has put across an opposing statement against oral piercings.

“The American Academy of Pediatric Dentistry strongly opposes the practice of piercing intraoral and perioral tissues and use of jewellery on intraoral and perioral tissues due to the potential for pathological conditions and sequelae associated with these practices”.³²

Ioannis et al, concluded that oral piercings results in harmful acute and chronic risk to both soft and hard tissues and they may eventually cause severe consequences.³ Cinzia et al., clearly explains how the oral hygiene practices changes after oral piercings.⁴but in our study only 72% students knew about this fact and rest were unaware of the context. According to Hennequin-Hoenderdos et al., the rising popularity of body piercings in young adults, is

determined by various factors, including the urge to fulfil social demands, establish a personal statement or enhance sexual appeal.³³ Whereas in our study, 71.3% students considered oral piercing as a fashion statement. Moreover only 5.8% students in our study knew that labrets are also used as an ornament. Dermata. A et al., suggests that as a part of history taking questions related to piercings should be included.¹⁹ O'Dwyer JJ and Holmes A in their article, clearly describes how a carelessly placed labret caused trauma to lower gingiva causing gingival recession.²⁸ In our study only 35.6% students' marked gingival recession as a complication of oral piercing which obviously states how gingival recession is not considered as a serious complication.

5. Conclusion

Dentists are the paramount professionals in detecting such complications and hence they should be well aware and so requires comprehensive knowledge regarding sequelae of oral and perioral piercings. Dental students on the other hand are upcoming dentists who will treat the upcoming generation and thus play an important role in educating their peer groups and other patients. Although many dental students had a knowledge regarding harmful complications of oral and perioral piercing, but many pages are returned with respect to its severity and how it affects the life of an individual after. Hence, students should encourage everyone to be aware of these ruinous procedures and discuss their detrimental effects with patients as much as they can. Students should also educate them about how the oral hygiene practices change after these jewellery, and how to properly maintain the oral hygiene.³³

6. Conflict of Interest

The authors declare that there are no conflicts of interest in this paper.

7. Source of Funding

None.

References

1. Pramod RC, Suresh KV, Kadashetti V, Shivakumar KM, Ingaleshwar PS, Shetty SJ. Oral piercing: A risky fashion. *J Educ Ethics Dent.* 2012;2(2):50-60.
2. Escudero-Castaño N, Perea-García MA, Campo-Trapero J. Oral and perioral piercing complications. *Open Dent J.* 2008;2:133-6. doi:10.2174/1874210600802010133.
3. Plastargias I, Sakellari D. The consequences of tongue piercing on oral and periodontal tissues. *Int Sch Res Notices.* 2014;doi:10.1155/2014/876510.
4. Maspero C, Farronato G, Giannini L, Kairyte L, Pisani L, Galbiati G, et al. The complication of oral piercing and the role of dentist in their prevention: a literature review. *Stomatologija.* 2014;16(3):118-24.
5. Singh A, Tuli A. Oral piercings and their dental implications: a mini review. *J Investig Clin Dent.* 2012;3:95-7.

6. D'dharan SR, Neelakantan P. Oral piercings: An art that destroys. *Int J Clin Dent*. 2013;6(4):361-6.
7. Farah CS, Harmon DM. Tongue piercing: case report and review of current practice. *Aust Dent J*. 1998;43(6):387-9. doi:10.1111/j.1834-7819.1998.tb00197.x.
8. Keogh JJ, O'leary G. Serious complication of tongue piercing. *J Laryngology Otol*. 2001;115(3):233-4.
9. Moor RJD, Witte AMD, Bruyne MAD. Tongue piercing and associated oral and dental complications. *Endod Dent Traumatol*. 2000;16(5):232-7. doi:10.1034/j.1600-9657.2000.016005232.x.
10. Shacham R, Zaguri A, Librus HZ, Bar T, Eliav E, Nahlieli O, et al. Tongue piercing and its adverse effects. *Oral Surg, Oral Med, Oral Pathol, Oral Radiol, Endodontology*. 2003;95(3):274-6.
11. Agarwal N, Iqbal H, Agarwal K, Mathur S, Saurabh S, Saha A, et al. Oral Piercing – Pain Or Pleasure?? A Review Article. *IOSR J Dent Med Sci*. 2014;13(10):20-6.
12. Levin L, Zadik Y. Oral piercing: complications and side effects. *Am J Dent*. 2007;20(5):340.
13. Lick SD, Edozie SN, Woodside KJ, Conti VR. Streptococcus viridans endocarditis from tongue piercing. *J Emerg Med*. 2005;29(1):57-66.
14. Friedel JM, Stehlik J, Desai M, Granato JE. Infective endocarditis after oral body piercing. *Cardiol Rev*. 2003;11(5):252-5.
15. Akhondi H, Rahimi AR. Haemophilus aphrophilus endocarditis after tongue piercing. *Emerg Infect Dis*. 2002;8(8):850-1.
16. Kretchmer MC, Moriarty JD. Metal piercing through the tongue and localized loss of attachment: a case report. *J Periodontol*. 2001;72(6):831-3.
17. Brooks JK, Hooper KA, Reynolds MA. Formation of mucogingival defects associated with intraoral and perioral piercing. *J Am Dent Assoc*. 2003;134(7):837-43.
18. Zadik Y, Sandler V. Periodontal attachment loss due to applying force by tongue piercing. *J California Dent Assoc*. 2007;35(8):550-3.
19. Dermata A, Arhakis A. Complications of oral piercing. *Balkan J Stomatology*. 2013;17(3):117-21.
20. Tabbaa S, Guigova IV, Preston CB. Midline diastema caused by tongue piercing. *J Clin Orthod*. 2010;44(7):426-8.
21. Levin L, Zadik Y, Becker T. Oral and dental complications of intra-oral piercing. *Dent Traumatol*. 2005;21(6):341-3.
22. Shinohara EH, Horikawa FK, Ruiz MM, Shinohara MT. Tongue piercing: case report of a local complication. *J Contemp Dent Pract*. 2007;8(1):83-9.
23. Er N, Özkavaf A, Berberoğlu A, Yamalik N. An unusual cause of gingival recession: oral piercing. *J Periodontol*. 2000;71(11):1767-9.
24. Campbell A, Moore A, Williams E, Stephens J, Tatakis DN. Tongue piercing: impact of time and barbell stem length on lingual gingival recession and tooth chipping. *J Periodontol*. 2002;73(3):289-97.
25. Brennan M, O'Connell B, O'Sullivan M. Multiple dental fractures following tongue barbell placement: a case report. *Dent Traumatol*. 2006;22(1):41-3.
26. Diangelis AJ. The lingual barbell: a new etiology for the cracked-tooth syndrome. *J Am Dent Assoc*. 1939;128(10):1438-9.
27. Fleming PS, Flood TR. Bifid tongue-a complication of tongue piercing. *Br Dent J*. 2005;198(5):265-6.
28. O'Dwyer J, Holmes A. Gingival recession due to trauma caused by a lower lip stud. *Br Dent J*. 2002;192(11):615-6.
29. Levin L. Alveolar bone loss and gingival recession due to lip and tongue piercing. *N York State Dent J*. 2007;73(4):48.
30. Tronel H, Chaudemanche H, Pechier N, Doutrelant L, Hoen B. Endocarditis due to Neisseria mucosa after tongue piercing. *Clin Microbiol Infect*. 2001;7(5):275-6.
31. Martinello RA, Cooney EL. Cerebellar brain abscess associated with tongue piercing. *Clin Infect Dis*. 2003;15(2):32-4.
32. Council O. Policy on Intraoral/Perioral Piercing and Oral Jewelry/Accessories; 2021. Available from: https://www.aapd.org/globalassets/media/policies_guidelines/p_intraoralpiercing.pdf.
33. Hennequin-Hoenderdos NL, Slot DE, Weijden GAVD. The prevalence of oral and peri-oral piercings in young adults: a systematic review. *Int J Dent Hyg*. 2012;10(3):223-8.

Author biography

Reshma RK, Intern

Sumit Bhateja, Professor and Head

Tamanna Soni, Senior Lecturer

Geetika Arora, Professor

Sheena T Arora, Senior Lecturer

Vineeta Charan, Tutor

Cite this article: Reshma RK, Bhateja S, Soni T, Arora G, Arora ST, Charan V. Oral and perioral piercings: Awareness and knowledge among undergraduate dental students in a private dental college, Haryana. *International Dental Journal of Student's Research* 2021;9(3):157-161.