



Case Report

Fabrication of ocular prosthesis step by step procedure: Case report

Jyotsna Vimal¹, Raghuwar Dayal Singh^{1,*}, Pooran Chand¹, Sunit Kumar Jurel^{1,*}

¹Dept. of Prosthodontics and Crown & Bridge, King George's Medical University UP, Lucknow, Uttar Pradesh, India



ARTICLE INFO

Article history:

Received 22-09-2020

Accepted 13-10-2020

Available online 24-10-2020

Keywords:

Enucleation

Ocular

Prosthesis

Scleral Shell

ABSTRACT

An ocular defect may follow removal of a part or an entire orbit that results in visual impairment as well as esthetically and psychologically handicapped. Losing eye is trauma not just to the patient but also for the family members. Restoring an ocular defect brings back esthetics but also the confidence that has been lost. Rehabilitation is also very important as this also preserves the contour of remaining structure. Different materials can be used for ocular defects rehabilitation like silicone or acrylic. This is a case report of a patient with a 'pthisical eye' and mainly focussed on the fabrication of an ocular prosthesis.

© 2020 Published by Innovative Publication. This is an open access article under the CC BY-NC license (<https://creativecommons.org/licenses/by-nc/4.0/>)

1. Introduction

Defect can be after trauma, tumour or congenital absence, sometimes infection are the main causes of such defects. Therefore, defect can cause loss of vision as well as esthetically handicapped.¹⁻³ surgical procedure which may include en bloc removal, exenteration or enucleation of only the eyeball.^{1,2,4-8} prosthetic eye replacement can prove beneficial for such patients.

A multidisciplinary approach including a prosthodontist, ophthalmologist, surgeon and are made to fit precisely the confines the contour of ocular socket of the patient. It replaces the sclera, Iris and sclera maxillofacial prosthodontist should be considered for an esthetic and stable outcome.^{2,5-7} Prosthetic eye matched according to contralateral eye. It maintains the esthetics but also protects eye cavity from infections.

Many techniques have been advocated in the past and published earlier. Present technique is also very simple and explained for pediatric patient. Technique explained here is step by step procedure for the fabrication of an ocular defect.^{2,5,6}

2. Case Report

A 5-year-old female patient reported to the Department of Prosthodontics and Crown & Bridge with a defect in her left eye.(Figure 1a) The defect was caused by retinoblastoma which is very common tumour of infancy & childhood. On inspection contents of eye has been removed due to carcinomatous growth, left muscles of an eye and eyelids intact.(Figure 1b) On examination: No inflammation was present, no pain, no sensitivity present. The muscle function of both the upper and lower eyelid seemed normal. Like many of the cases reported in our department, for this case also we decided to fabricate a Custom ocular prosthesis.

3. Method of fabrication of the ocular prosthesis

3.1. Impression tray selection

Select acrylic ocular impression tray or old conformer according to the fit of the socket .Patient needs to be in relaxed position to drape the natural contours of the tissues of the socket. Impression tray can be modified according to size of the socket. The margins can be smoothed with the help of Finishing bur (Prisma finishing bur #T-6) to prevent any irritation inside the socket.

* Corresponding authors.

E-mail address: sunitknu1977@gmail.com (S. K. Jurel).

3.2. Impression

For this patient we decided to take impression using Light body Addition silicone material. (Figure 2 a) For taking impression patient is asked to look straight and impression material injected into the selected impression using syringe and slowly fill the defect and patient is asked to move his eye slowly in all the directions. small amount of material should flow out from inner canthus. The impression was gently removed first by massaging the lower lid downwards and away from the nose first and then sliding the impression out from the upper eyelid in an arc like path. The impression was then washed and disinfected with Revita lens solution (Ocutec, UK).

3.3. Making a stone model

A stone model is made of the impression. Take the stone in small mold fill it and then place the impression over it and remove the impression from the syringe. Then apply vaseline over the first pour and then second pour is poured over the first pour in small mold itself. (Figure 2b)

3.4. Making a wax pattern

Model which is made is used for wax pattern fabrication. a light yellow wax (Technovent Ltd, southwales and UK) was pour over the first mold and second layer of mold. (Figure 3a) on hardening the wax pattern, retrieve it gently and smoothed with the help of a carver and guaze. Try the wax pattern in patients eye and adjust accordingly. It should not look bulky and nor even under filled. (Figure 3b) wax pattern should fit in eye properly and should not come out while moving eye in all directions.

3.5. Attaching the iris

In this case colour matched iris selected from acrylic stock eye, and iris matched with adjacent eye and cut from stock eye and placed over the wax pattern with normal gaze. Iris should coincide with the size of adjacent eye (range 11-13 mm with an average of 12mm). while placing the patient should look medial and downward at this stage. Various techniques has been described in past for iris positioning. For this case we used graph method to place the iris. Once the iris is positioned it should be flaked in two part flask using dental plaster. Curing is to be done according to conventional technique. (Figure 4 a,b)

Colour matching done using tooth coloured heat cured acrylic resin and using acrylic paints sclera should match with the adjacent eye.

As patient is pediatric patient, instructions given to the parents, how to insert & remove the prosthesis without hurting the patient. Its also important to take care about the hygiene of the prosthesis. All the instructions given to the patient's parents. It has also been explained that prosthesis

might need repolishing at some intervals.

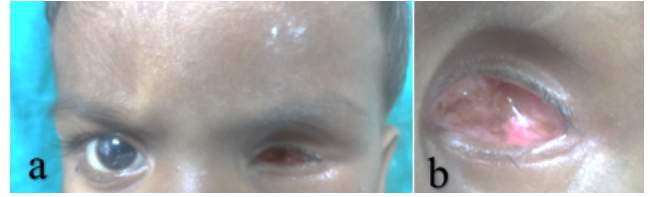


Fig. 1: a patient with ocular defect, b ocular bed



Fig. 2: a Impression made using light body Addition silicone, b stone model made



Fig. 3: a. Wax pattern for trial, b. Wax pattern tried in patients eye

4. Discussion

Prosthesis given to the patient not just improves esthetics but also prevent social embarrassment. As in this case patient is pediatric patient so its important to maintain the size of the ocular defect otherwise it leads to microphthalmia and its then very difficult to restore such defects. technique described here is simple and can be easily tried.

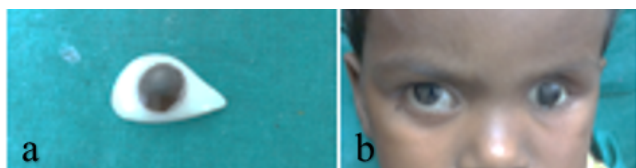


Fig. 4: a complete ocular prosthesis, b: final prosthesis tried in patients eye

5. Conclusion

A prosthetic eye is a ray of hope for patients with an ocular defects to restore esthetics and prevents psychological trauma. An ocular eye is not just restoring ethetics but also restoring remaining structures of eye. But inefficient to restore visison.

6. Source of Funding

None.

7. Conflict of Interest

None.

References

1. Raflo GT. Enucleation and evisceration. In: Tasman W, Jarger E, editors. Duane's Clinical Ophthalmology. vol. 5. Lippincott Williams and Wilkins; 1995. p. 1–25.

2. Patil SB, Meshramkar R, Naveen BH, Patil NP. Ocular prosthesis: a brief review and fabrication of an ocular prosthesis for a geriatric patient. *Gerodontology*. 2008;25(1):57–62.
3. Taicher S, Steinberg HM, Tubiana I, Sela M. Modified stock-eye ocular prosthesis. *J Prosth Dent*. 1985;54(1):95–8.
4. Lal S, Schwartz A, Gandhi T, Moss M. Maxillofacial Prosthodontics for the Pediatric Patient: "An Eye-Opening Experience". *J Clin Pediatr Dent*. 2007;32(1):5–8.
5. Guttal SS, Joshi SM, Pillai LK, Nadiger RK, Gerodontology. Ocular prosthesis for a geriatric patient with customised iris: A report of two cases. *Gerodontology*. 2011;28:152–6.
6. Ioli-Ioanna A, Montgomery PC, Wesley PJ, Lemon JC. Digital imaging in the fabrication of ocular prostheses. *J Prosth Dent*. 2006;95(4):327–30.
7. Bartlett SO, Moore DJ. Ocular prosthesis: A physiologic system. *J Prosth Dent*. 1973;29(4):450–9.
8. Perman KI, Baylis HI. Evisceration, Enucleation, and Exenteration. *Otolaryngologic Clin North Am*. 1988;21(1):171–82.

Author biography

Raghuwar Dayal Singh Professor

Pooran Chand Professor and Head

Sunit Kumar Jurel Junior Professor

Cite this article: Vimal J, Singh RD, Chand P, Jurel SK. Fabrication of ocular prosthesis step by step procedure: Case report. *Int Dent J Students Res* 2020;8(3):125-127.