



## Case Report

# Prosthetic management of large ocular defect using lost salt technique – Case report

Jyotsna Vimal<sup>1</sup>, Virendra Singh<sup>1</sup>, Sunit Kumar Jurel<sup>1</sup>, Raghuwar Dayal Singh<sup>1,\*</sup>, Pooran Chand<sup>1</sup>

<sup>1</sup>Dept. of Prosthodontics and Crown & Bridge, King George's Medical University, Lucknow, Uttar Pradesh, India



### ARTICLE INFO

#### Article history:

Received 07-09-2020

Accepted 06-10-2020

Available online 24-10-2020

#### Keywords:

Ocular prosthesis

ocular defect

Lost salt technique

Hollow prosthesis

### ABSTRACT

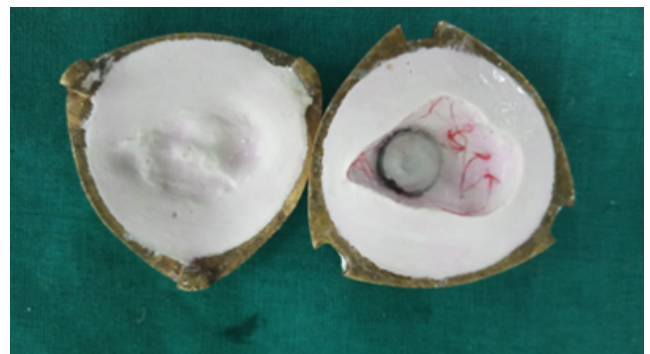
An ocular defect can be due to many reasons such as congenital absence of an eye and acquired causes which occurs due to enucleation or exenteration procedure. Ocular defects requires urgent rehabilitation to prevent further changes and to prevent shrinkage. In this article we are going to describe a for fabrication of a prosthesis that should be light weighted (pneumatic) using a lost salt technique basically to reduce the weight of prosthesis for large socket, to overcome the worsening effects of conventional solid prosthesis.

© 2020 Published by Innovative Publication. This is an open access article under the CC BY-NC license (<https://creativecommons.org/licenses/by-nc/4.0/>)

## 1. Introduction

Several studies which has been described in the past for ocular prosthesis fabrication for cases of excessive orbital volume various techniques have also been described .Excessive volume loss occurs due to various reasoned for which needs to underwent enucleation or exenteration procedure. An abnormally large orbital defect created that require equally sized volume prosthesis to fir completely and avoid impingement of lower fornix and weight should also be less. otherwise impingement due to extended prosthesis lower fornix dehiscence occurs and it might cause assymetrical alignmnet of entire palpebral fissure. therefore, therefore to solve the problems of bulky ocular prosthesis. Turn<sup>1</sup> Dias<sup>2</sup> and Aggarwal H<sup>3,4</sup> have demonstrated techniques for making hollow artificial eyes. Dias<sup>2</sup> proposed using Styrofoam in acrylic resin in order to lessen the burden of these prostheses, providing greater range of motion, comfort and preventing deformity of the anophthalmic socket. Aggarwal H proposed method using lost wax technique for the fabrication of light weighted

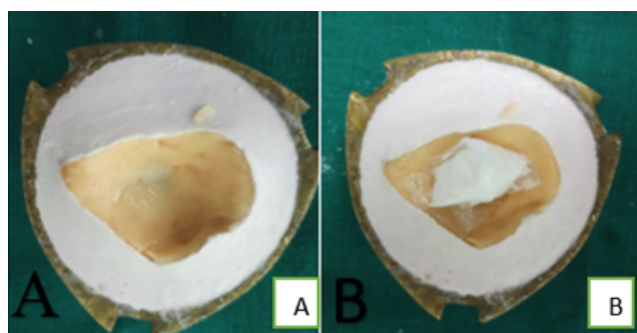
prosthesis.<sup>4</sup> In this paper we are going to describe a new technique for fabricating a pneumatic custom ocular prosthesis for large ophthalmic cavities by using lost Salt technique, in order to reduce the weight of the prosthesis and thus improving mobility, comfort and aesthetics apart from preventing lower lid distortion and/or asymmetrical alignment of the entire palpebral fissure.



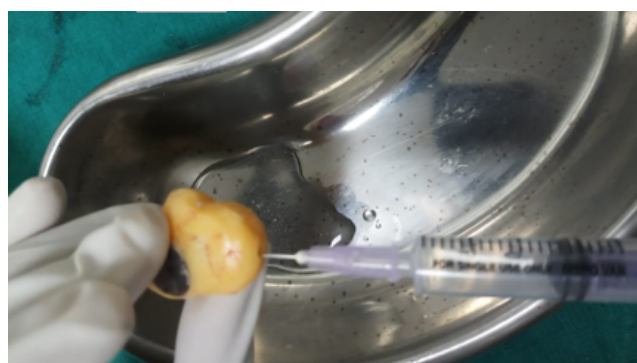**Fig. 1:** Dewaxed moulds with application of veins in drag portion of flask

\* Corresponding author.

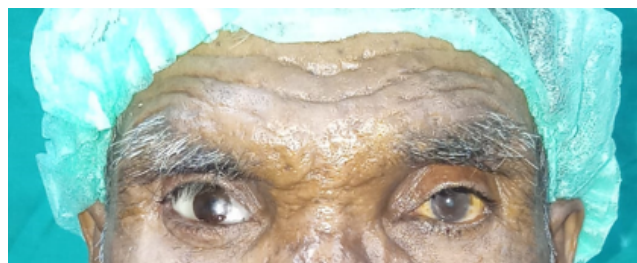E-mail address: [raghuwards@rediffmail.com](mailto:raghuwards@rediffmail.com) (R. D. Singh).



**Fig. 2:** (A): Application of acrylic resin in drag portion of flask, (B) salt in packet placed over first layer of acrylic resin.



**Fig. 3:** Final prosthesis removing salt through saline-filled in syringe by making holes in final prosthesis.



**Fig. 4:** Patient wearing final prosthesis

## 2. Materials and Methods

1. Place the perfectly shade matched tooth-colored heat polymerized acrylic resin (DPI, Mumbai, India) to a thickness of about 2 mm, in the drag part of flask containing iris, to form the polished surface of the prosthesis (Figure 2 A).
2. Place salt packed in small plastic packet over it and spread it uniformly over the first layer of acrylic resin leaving 1mm margin over all (Figure 2B).
3. Mix accordingly and place the layer of heat cured acrylic resin as second layer over it and left for bench curing for 30 minutes.
4. Do gross finishing carefully after retrieving the cured ocular prosthesis.

5. Make two small holes in intaglio surface of prosthesis to allow escape for salt (Figure 3).
6. Take saline in 5ml syringe and needle can be placed in one hole and salt mixed water will come out from other hole (Figure 3).
7. After the removal of salt completely from prosthesis escape holes can be easily seal using auto polymerizing resin (SC 10, Pyrax, Roorkee, India) thus obtaining a pneumatic prosthesis.
8. Place the final prosthesis in the patient eye and evaluate the appearance and esthetic (Figure 4).

Final prosthesis removing salt through saline-filled in syringe by making holes in final prosthesis.

## 3. Discussion

The technique described in this article to overcome the problems of large ocular defects and to make prosthesis as light as possible and to prevent the deteriorating effects of voluminous prosthesis on lower lid seems very simple, logical, cost effective approach. The technique described needs care while placing a second layer of acrylic resin, that make sure 1-2mm acrylic resin should be free from salt while placing it on first layer so that second layer can attach with first layer. As salt can easily be come out from prosthesis without leaving any residue, this technique has its advantage and making the prosthesis hollow. Light weighted Prosthesis is always comfortable and provides ultimate goal of concealment.

## 4. Conclusion

The technique described here in order to reduce the weight the prosthesis is very simple, logical and cost effective approach to rehabilitate the large ocular defects and to prevent the lower lid distortion and to prevent misalignment of palpebral fissure associated with conventional solid ocular prosthesis. This technique can be used by anyone very effectively

## 5. Source of Funding

None.

## 6. Conflict of Interest

None.

## References

1. Turn R. Ocular prosthesis hollow acrylic resin. *Rev Odontol Univ Sao Paulo.* 1975;13:55–60.
2. Dias RB. Light-weight ocular prosthesis. *Braz Dent J.* 1994;5:105–8.
3. Aggarwal H. Rehabilitation of phthisis bulbi: a case report. *J Pak Dent Assoc.* 2012;1(2):113–11.
4. Aggarwal H, Kumar P, Singh RD. A Simplified Method to Fabricate a Pneumatic Ocular Prosthesis for Large Ocular Defects. *J Indian Prosthodont Soc.* 2014;14(1):S106–9.

**Author biography****Jyotsna Vimal** Resident**Virendra Singh** Resident**Sunit Kumar Jurel** Junior Professor**Raghuwar Dayal Singh** Professor**Pooran Chand** Professor and Head

**Cite this article:** Vimal J, Singh V, Jurel SK, Singh RD, Chand P. Prosthetic management of large ocular defect using lost salt technique – Case report. *Int Dent J Students Res* 2020;8(3):122-124.