

## Can there be a more precise co-relation between grades of sinusitis, concha bullosa and deviated nasal septum- A CBCT evaluation

Mayuri Jaitley<sup>1</sup>, Sanchita Kant<sup>2\*</sup>, Himadri Verma<sup>3</sup>, Swati Kant<sup>4</sup>, Manoj Samant<sup>5</sup>

<sup>1,3</sup>Senior Lecturer, <sup>2,4,5</sup>Consultant, Dept. of Oral Medicine & Radiology, <sup>1-3</sup>Sri Aurobindo College of Dentistry, Indore, Madhya Pradesh, <sup>4</sup>SRT Medical College, Ambejogai, Maharashtra, <sup>5</sup>BJ Medical College, Pune, Maharashtra, India

**\*Corresponding Author: Sanchita Kant**

Email: sanchitakant@gmail.com

### Abstract

Computerized tomographic imaging of the nasal and paranasal regions is frequently used for sinonasal surgery. CBCT is another less explored modality which can provide accurate anatomic details. A retrograde study was done on 204 random scans to find out incidence and prevalence of sino-nasal anatomical variations and associated pathologies. A positive correlation was found between deviated nasal septum and concha bullosa. CBCT can surely act as a guide in future for sinonasal surgeries with lesser cost and radiation exposure.

**Keywords:** CBCT, Deviated nasal septum, Concha bullosa, Chronic sinusitis.

### Introduction

The maxillary sinus is a pyramidal structure, dark or low in density. The reason behind this dark appearance is credited to minimal attenuation of x-rays by the air voids. Thus a “not dark” appearance signifies some or the other pathology. In Cone Beam Computed Tomography (CBCT), coronal images are the most appropriate aide for viewing the co-relation of sinuses and nasal cavity. Specifically the maxillary sinuses and nasal structures can be best visualized at the level of maxillary molars.<sup>1</sup>

The nasal septum is seen in the midline of the nasal cavity. It is seldom completely ossified. The position of the nasal septum may contribute to the asymmetry between the right and left sides.<sup>1</sup> It extends from roof to the floor of nasal cavity, with the cribriform plate lying superiorly and hard palate inferiorly. The anterior extent of nasal septum is defined by the septal cartilage and the posterior extent by perpendicular plate of ethmoid bone.<sup>2</sup>

From the lateral wall of the nasal cavity arise three projections- the superior, middle and inferior conchae.<sup>3</sup> Of these, only the inferior concha is an independent bone, other two being parts of the ethmoid bone.<sup>1</sup>

Histopathologically, sinusitis is defined as inflammation of the nasal and paranasal sinus mucosa.

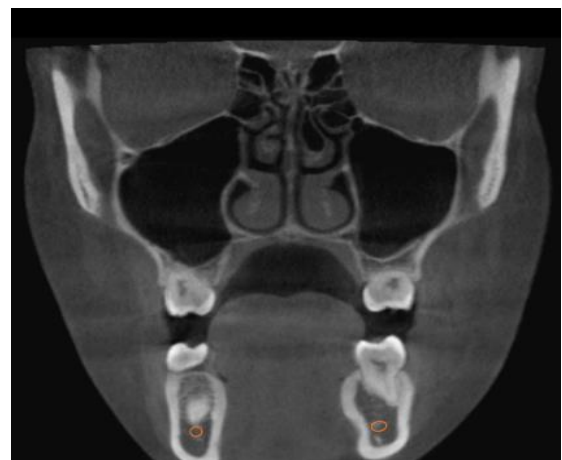It results most commonly from pneumatization of conchae called concha bullosa (CB), deviated nasal septum (DNS) and Haller cells.<sup>4</sup> Although it can be found in any of the three conchae, it is most frequently encountered in the middle one.<sup>5</sup>

Bolger et al classified the conchae into 3 types (shown in Fig. 1,2 and 3): lamellar concha bullosa (LCB), bulbous

concha bullosa (BCB) and extensive concha bullosa (ECB).<sup>5</sup> Various studies have so far suggested a variable prevalence of CB (35% to 53%), while that of DNS ranges from 19.4%- 65%.<sup>6</sup>

While on one hand, some authors believe that the presence of CB points to sinusitis, others are convinced that CB merely acts as a predisposing factor for developing chronic sinusitis. In fact, studies have shown that CB leads to formation of nasal polyp, due to increased contact area.<sup>4</sup> The exact pathological process responsible for the co-relation between the two entities is not yet deciphered completely.<sup>5</sup>

This study was carried out to evaluate the co-relation between CB, DNS and various grades of Sinusitis and to find the prevalence of CB and DNS in general population.



**Fig. 1:** Lamellar

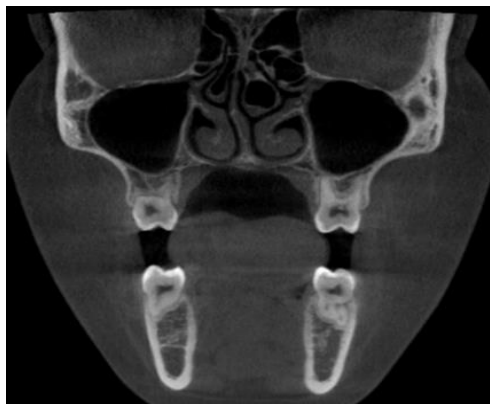


Fig. 2: Bulbous

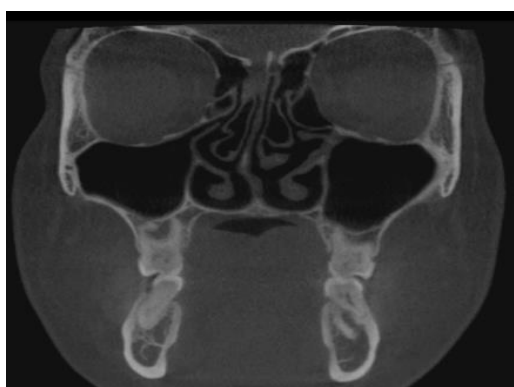


Fig. 3: Extensive

### Materials and Methods

This cross sectional study was held in the department of Oral Medicine & Radiology at Sri Aurobindo College of Dentistry, Indore. The layout of the study was such that evaluation of CB, DNS and Sinusitis could be done, along with analysis of their co- relation with ease. The protocols of the study were approved by the Local Ethical Committee at Sri Aurobindo College of Dentistry, Indore.

204 (116 males, 88 females) full volume CBCT scans with adequate visualization of the nasomeatal complex were included in the study. Scans excluded were the ones with craniofacial anomalies and other significant anomalies affecting the concerned region. All individuals whose scans were a part of the study were above the age of 18 years.

Scans were imported in the OnDemand3D App, Medical Imaging Software (CyberMed, Seoul, Korea). Following parameters were included in the study:

**CB:** the presence of pneumatization of *any size* within in the superior, middle, or inferior conchae. CB was looked for in both conchae and was measured in square mm.

**Septal deviation:** a deviation of *greater than 4mm* from the midline

**Sinusitis:** The grading for opacification of maxillary sinus was considered as follows:

1. Grade 1: sinonasal cavity completely opacified;
2. Grade 2: more than 75% opacification;
3. Grade 3: more than 50% opacification;
4. Grade 4: more than 25% opacification;
5. Grade 5: no to 25% opacification.<sup>7</sup>

**Deviated Septal Length (DSL):** Measurement of the horizontal distance from the most lateral point of deviated septum to the ideal location of the septum along vertical axis (Fig. 4).

**Deviated Septal Curve Angle (DSCA):** Obtuse angle between the highest point of the deviated septum and the line between crista galli (superiorly) to "P" (point of intersection of the perpendicular line passing through crista galli to the palatal bone) (inferior).<sup>3</sup> (Fig. 5)

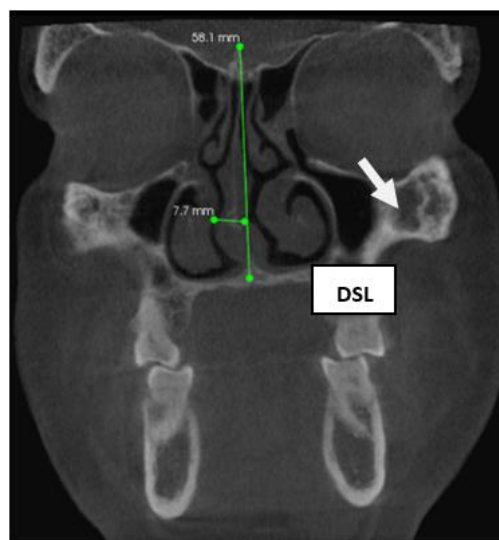


Fig. 4

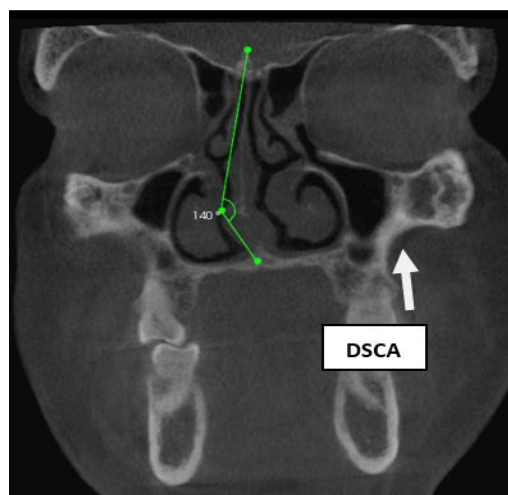
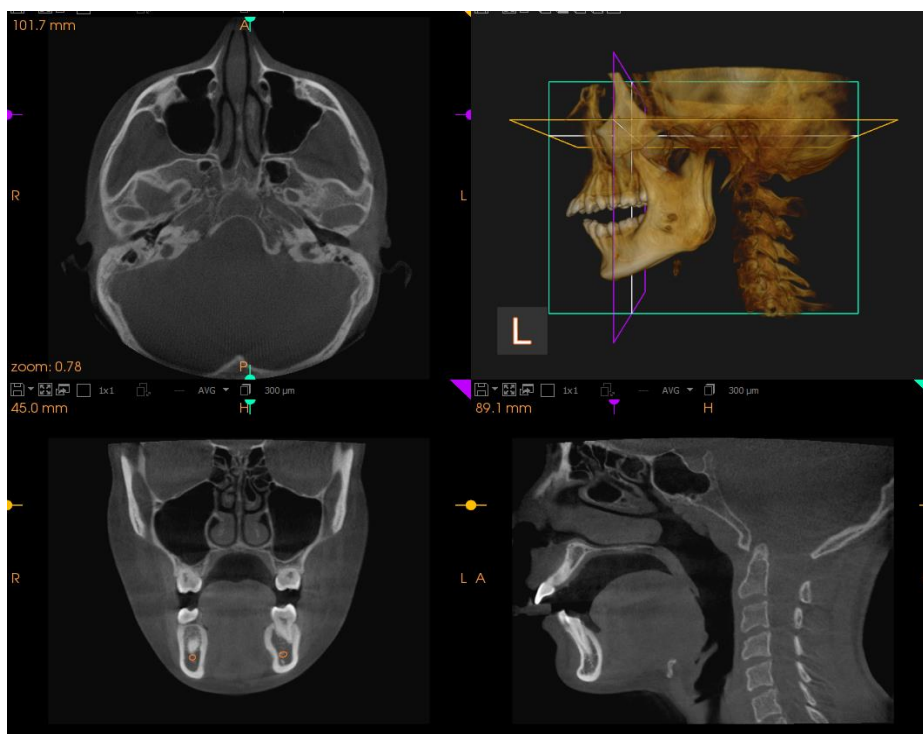


Fig. 5

Standardisation of scans was done at the level of 1<sup>st</sup> molars as depicted in Fig. 6. The measurements were done under the supervision of two well trained oral radiologists.



**Fig. 6:** Standardisation of scans at the level of 1<sup>st</sup> molars.

**Statistical analysis**

Both descriptive and inferential methods were part of the statistical analysis. The Pearson’s Chi-Square test was used to decipher the association of maxillary sinusitis with CB and DNS; CB with DNS. Prevalence of CB, sinusitis and DNS was identified. The probability value  $p \leq 0.05$  was considered as significant while  $p \leq 0.001$  was considered as highly significant.

**Results**

Table 1 depicts the prevalence of CB, DNS, and sinusitis. Of the 204 scans, CB found in 135 (66.2%), making it more common than sinusitis present in 95 (46.6%) patients. DNS was present in 78 (38.2%) patients.

**Table 1:** Prevalence and gender distribution of CB, DNS and Sinusitis

Parameter	Concha Bullosa		Nasal Septal Deviation		Sinusitis	
	Absent	Present	Absent	Present	Absent	Present
<b>Total</b>	69 33.8%	135 66.2%	126 61.8%	78 38.2%	109 53.4%	95 46.6%
<b>Male</b>	42 60.9%	74 54.8%	72 57.1%	44 56.4%	54 49.5%	62 65.3%
<b>Female</b>	27 39.1%	61 45.2%	54 42.9%	34 43.6%	55 50.5%	33 34.7%
<b>p-value LOS</b>	$\chi_1^2 = 0.68$ ; $p=0.409$ <sup>⊗</sup>		$\chi_1^2 = 0.01$ ; $p=0.918$ <sup>⊗</sup>		$\chi_1^2 = 5.12$ ; $p=0.024$ <sup>*</sup>	

Table 2 presents the grading of sinusitis. The most common grade of sinusitis was found to be grade V in 55.8 cases, followed by grade IV (24.2%), grade III (7.4%).

**Table 2:** Characteristics of sinusitis

Parameter (Grading)		Total (N=95)	
		N	%
Sinusitis	Grade I	5	5.3
	Grade II	7	7.4
	Grade III	7	7.4
	Grade IV	23	24.2
	Grade V	53	55.8

The features and characteristics of NSD are shown in table 3. Of 204 scans, DNS was seen in 78 scans, with right side being more commonly involved (41).

**Table 3:** Characteristics of DNS

Parameter and affected Side		Mean ± Std. Deviation (mm and degree)	Range	
			Min	Max
Angle of deviated septal curve (°)	Total (N=78)	5.68 ± 1.30	4	10
	Left (n <sub>1</sub> =37)	148.00± 8.41	129	163
	Right (n <sub>2</sub> =41)	147.27± 8.44	128	164
	Total (N=78)	147.62 ± 8.38	128	164

The relationship of sinusitis with CB is presented in table 4. Forty seven out of 204 (34.8%) cases had with both CB and sinusitis. Sinusitis alone was found in 48 (69.6%) while CB alone was diagnosed in 88 (65.2%) scans. The statistical analysis indicated that the sinusitis was found to be a significant factor that strongly affected CB.

**Table 4:** Relationship of sinusitis and CB

Sinusitis	Concha Bullosa		Total
	Absent	Present	
Absent	21 30.4%	88 65.2%	109 53.4%
Present	48 69.6%	47 34.8%	95 46.6%
Total	69 100.0%	135 100.0%	204 100.0%
$\chi^2_1 = 22.16$ and $p=0.000$ #			

Table 5 shows the relationship between sinusitis with NSD. Out of total patients, 95 (46.6%) patients presented with sinusitis and 78 (38.24%) patients had DNS. Sinusitis alone was seen in 70 (55.6%) cases while DNS alone was diagnosed in 53 (67.9%) cases. But, twenty five (32.1%) cases had both DNS and sinusitis.

The relationship between the presence of sinusitis and DNS was found to be statistically strongly significant. Thus, the statistical agreement indicated that sinusitis is a significant factor that strongly impacted the DNS.

**Table 5:** Relationship of sinusitis and DNS

Sinusitis	Nasal Septum Deviation		Total
	Absent	Present	
<b>Absent</b>	56 44.4%	53 67.9%	109 53.4%
<b>Present</b>	70 55.6%	25 32.1%	95 46.6%
<b>Total</b>	<b>126</b> <b>100.0%</b>	<b>78</b> <b>100.0%</b>	<b>204</b> <b>100.0%</b>
$\chi_1^2 = 10.70$ and $p=0.001$ #			

Table 6 highlights the relationship of CB with DNS. Of all patients, 135 (66.2%) patients had CB as compared to 78 (38.24%) who had DNS.

The CB seen in 88 (69.8%) cases had no evidence of DNS, while DNS seen in 31 (39.7%) cases had no evidence of CB. But, forty seven (60.3%) cases had both DNS and CB.

Thus, statistically, CB is not a significant factor that impacts DNS.

**Table 6:** Relationship of CB and DNS

Concha bullosa	Nasal Septum Deviation		Total
	Absent	Present	
<b>Absent</b>	38 30.2%	31 39.7%	<b>69</b> <b>33.8%</b>
<b>Present</b>	88 69.8%	47 60.3%	<b>135</b> <b>66.2%</b>
<b>Total</b>	<b>126</b> <b>100.0%</b>	<b>78</b> <b>100.0%</b>	<b>204</b> <b>100.0%</b>
$\chi_1^2 = 1.98$ and $p=0.160$ ©			

**Discussion**

Chronic rhino sinusitis is a common condition causing frequent complications and morbidity. Chronic sinusitis has frequently been reported with presence of a deviated nasal septum. DNS can cause difficulty in normal drainage of mucus causing obstructions and secondary infections. Presence of CB has also been linked to frequent sinus infections. Literature has reported occurrence of CB between 14-54%. A frequent association between deviated septum and concha bullosa has been reported in past. These studies have revealed a strong association between DS and/or CB with sinusitis.<sup>8</sup> In patients with chronic sinusitis a thorough anatomic scan is frequently recommended to find and treat the etiology. Computed tomography is often used to study anatomical variations and plan the surgeries. However CT scan are associated with higher radiation exposure and are expensive. Use of CBCT can overcome these limitations. Very few studies using CBCT have been published in past. The aim of this

study was to highlight use of CBCT to identify the anatomical variations of the nasal septal configurations.

Our study shows a positive relation between anatomical variations and sinus pathologies. 34.8% patients had CB and sinusitis. It concludes that the presence of CB is a strong factor for incidence of sinusitis. Coronal sections are better to view anatomical variations as compared to axial sections. A presurgical CBCT scan can help plan accurate result and outcome. CBCT can revolutionize the ENT surgeries presently been conducted.

**Conclusion**

This study showed strong correlation between deviated nasal septum and concha bullosa with rhinosinusitis. To conclude, anatomic variations are frequent cause of rhino-sinusitis. CBCT scans are highly accurate and economical means to identify anatomic variations. Our study is a unique study demonstrating CBCT and its applications in ENT field.

**Source of funding**

None.

**Conflict of interest**

None.

**References**

1. Angelopoulos C. Cone Beam Tomographic Imaging Anatomy of the Maxillofacial Region. *Dent Clin N Am* 2008;52(4):731–52
2. Kajan ZD, Khademi J, Nemati S et al. The Effects of Septal Deviation, Concha Bullosa, and Their Combination on the Depth of Posterior Palatal Arch in Cone-Beam Computed Tomography. *Dent Shiraz Univ Med Sci* 2016;17(1):26-31.
3. Sevinc O, Barut C, Kacar D, Is M. Evaluation of the lateral wall of the nasal cavity in relation to septal deviation. *Int J Morpho* 2013;31:438-43.
4. Stammberger H, Posawetz W. Functional Endoscopic Sinus Surgery – Concept, indications and results of the Messerklinger Technique. *Eur Arch Otorhinolaryngol* 1990;247(2):63-76.
5. Bolger WE, Butzin CA, Parsons DS. Paranasal sinus bont anatomic variations and mucosal abnormalities: CT analysis for endoscopic sinus surgery. *Laryngoscope* 1991;101:56-64.
6. Smith KD, Edwards PC, Saini TS. The Prevalence of Concha Bullosa and Nasal Septal Deviation and Their Relationship to Maxillary Sinusitis by Volumetric Tomography. *Int J Dent* 2010;2010(404982):5. <https://doi.org/10.1155/2010/404982>.
7. Kei PL, Tan JSP, Leong JL. Cone-beam Computed Tomography of the Paranasal Sinuses: Comparison Study with Multidetector Computed Tomography. *Hong Kong J Radiol* 2013;16:110-6.
8. Taher, Waleed A. Abdel Hameed, Mohamad Hasan Alam-Eldeen, Ahmad Haridy. Coincidence of Concha Bullosa with Nasal Septal Deviation; Radiological Study Mostafa El. *Indian J Otolaryngol Head Neck Surg* 2019;71(3):1918-22.

**How to cite this article:** Jaitley M, Kant S, Verma H, Kant S, Samant M. Can there be a more precise co-relation between grades of sinusitis, concha bullosa and deviated nasal septum- A CBCT evaluation. *Int Dent J Student Res* 2019;7(4):115-20.